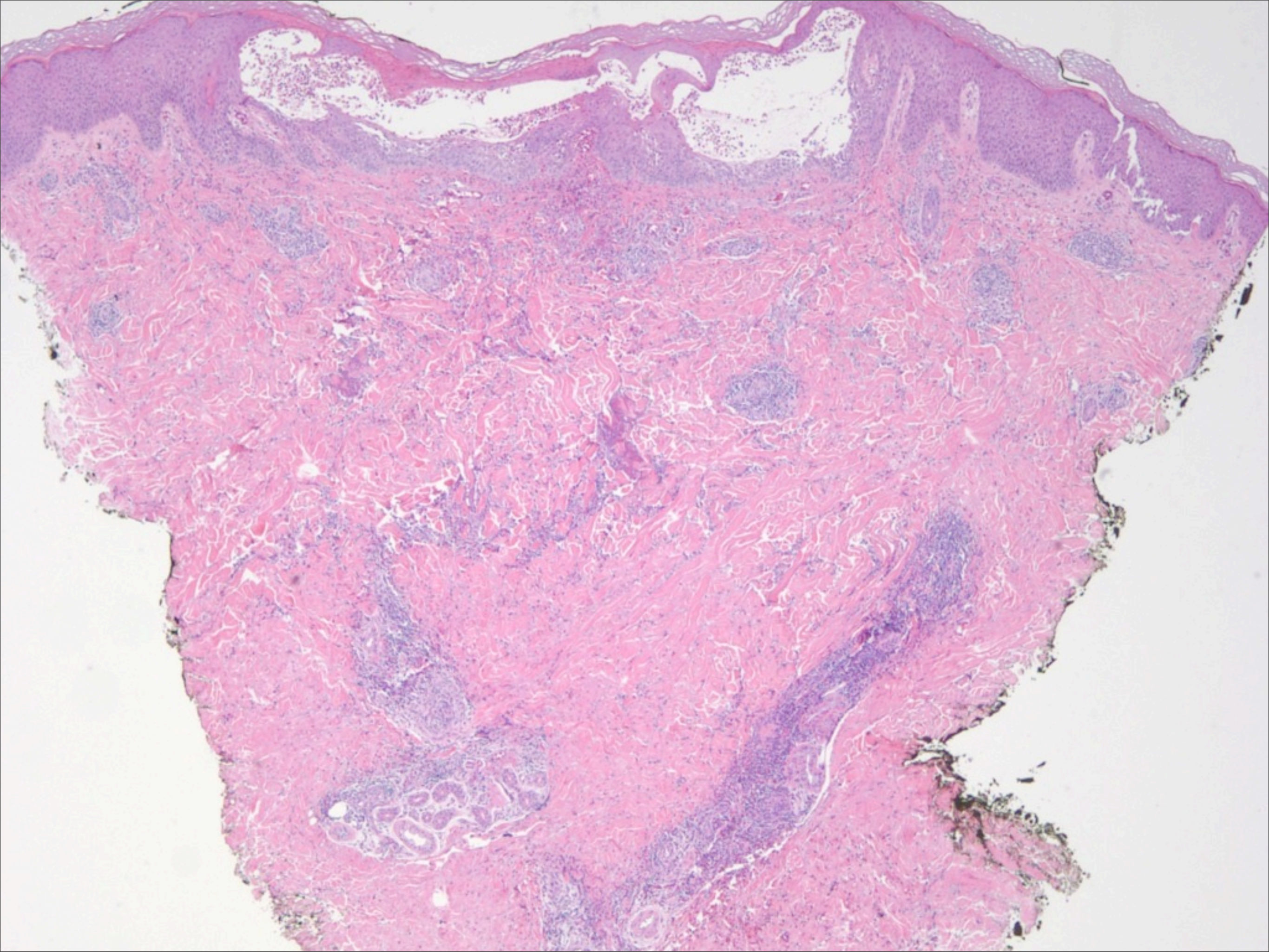
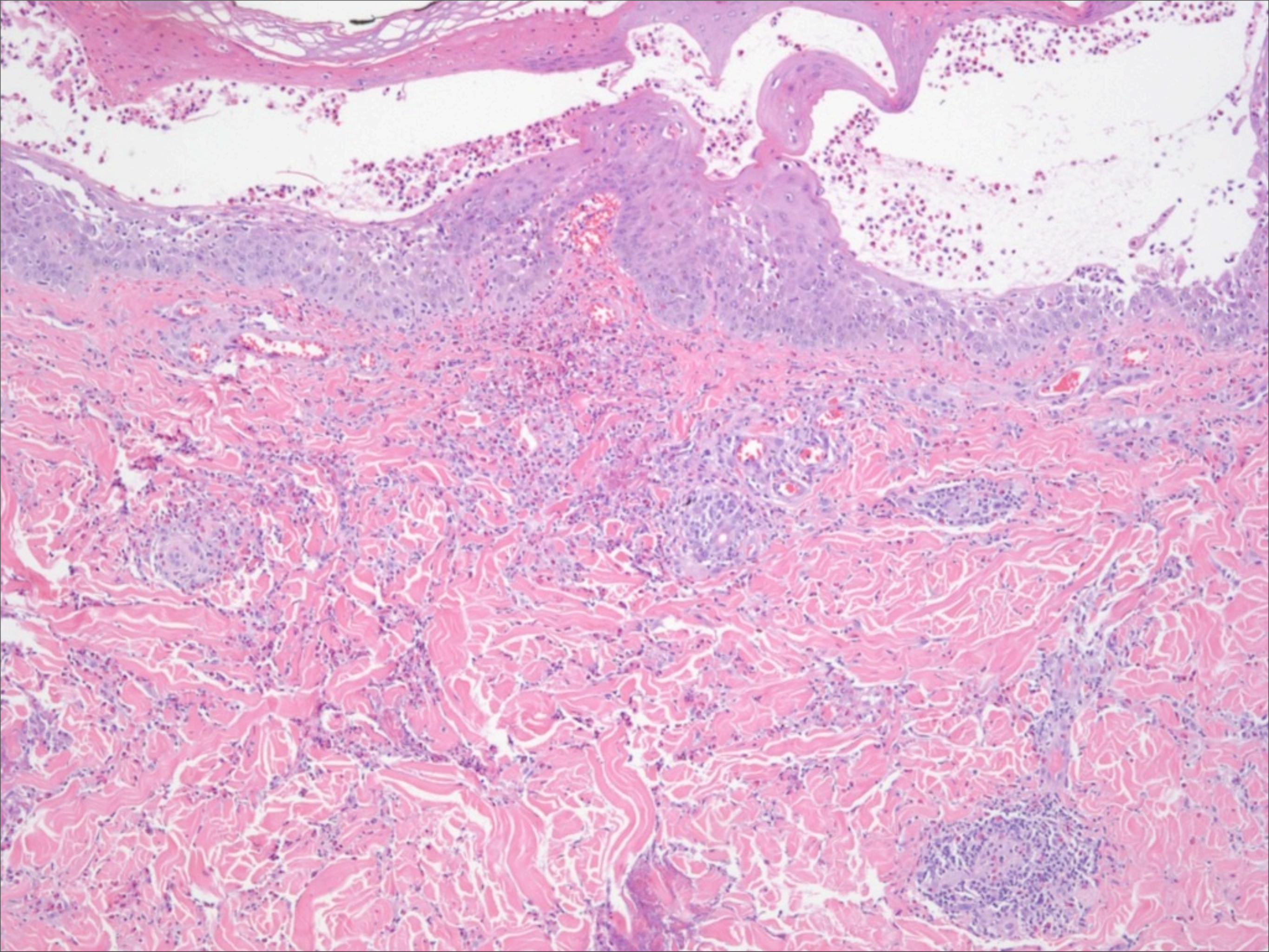


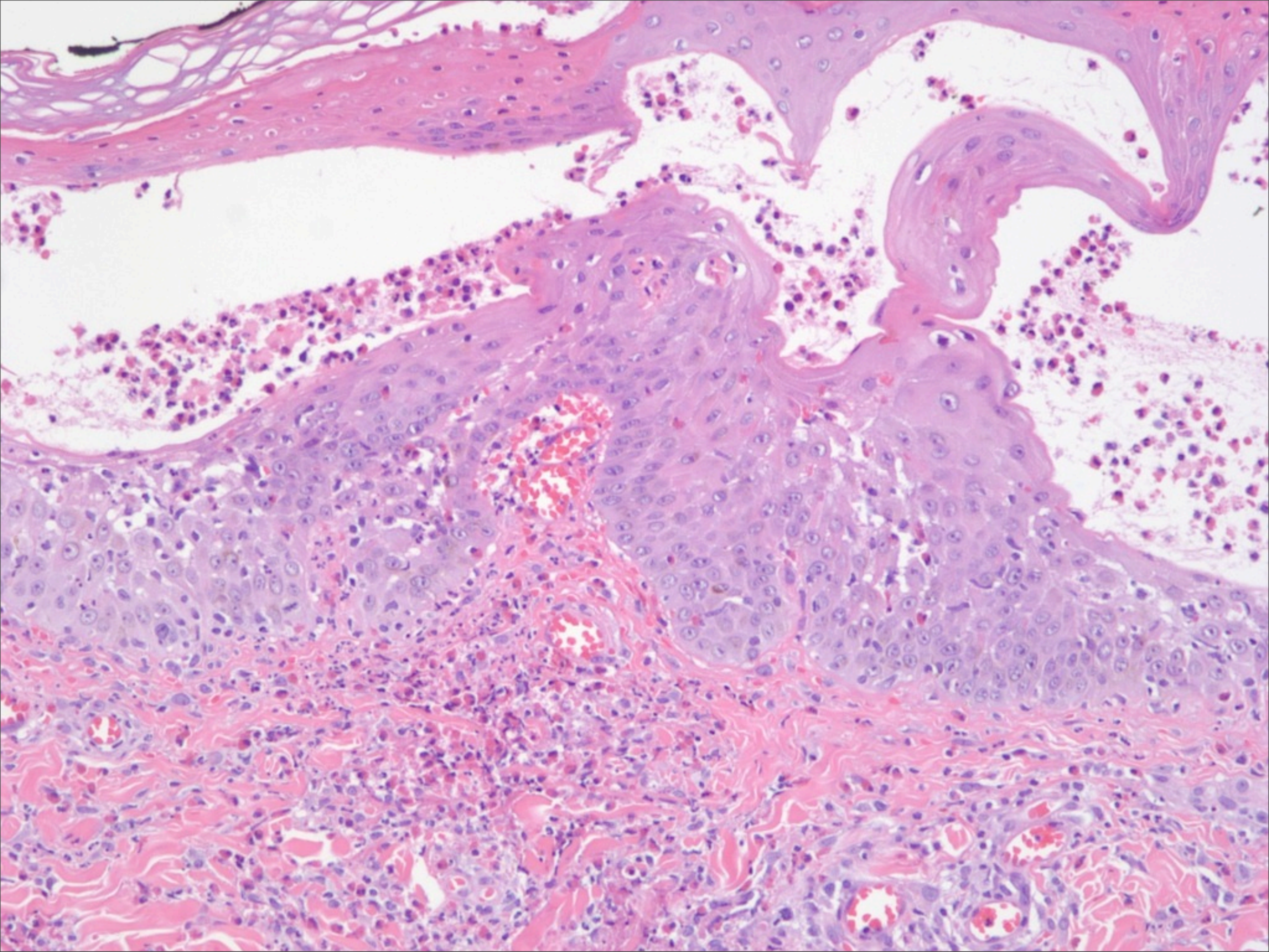
Dermatopathology

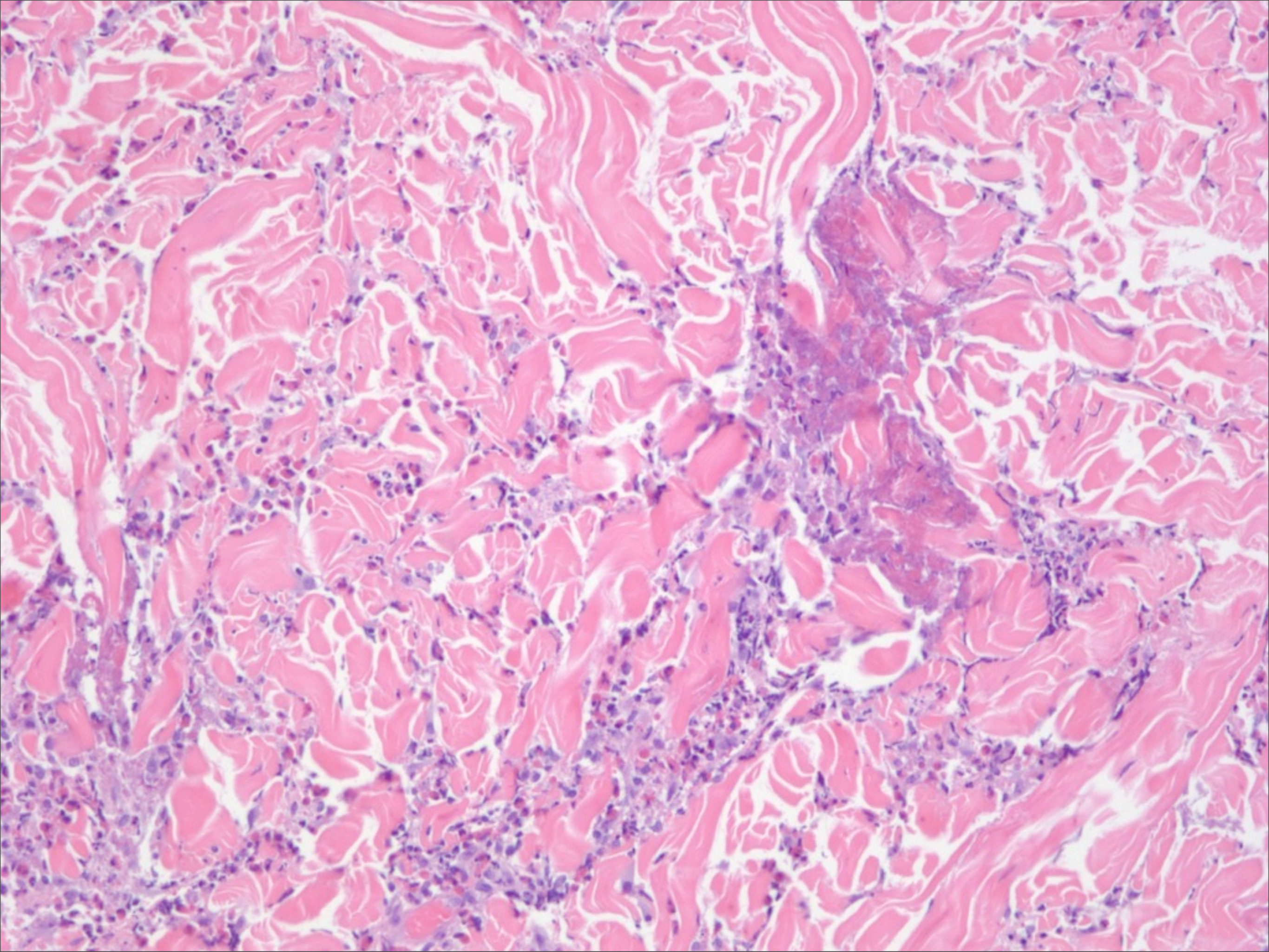
Slide Review Part 146

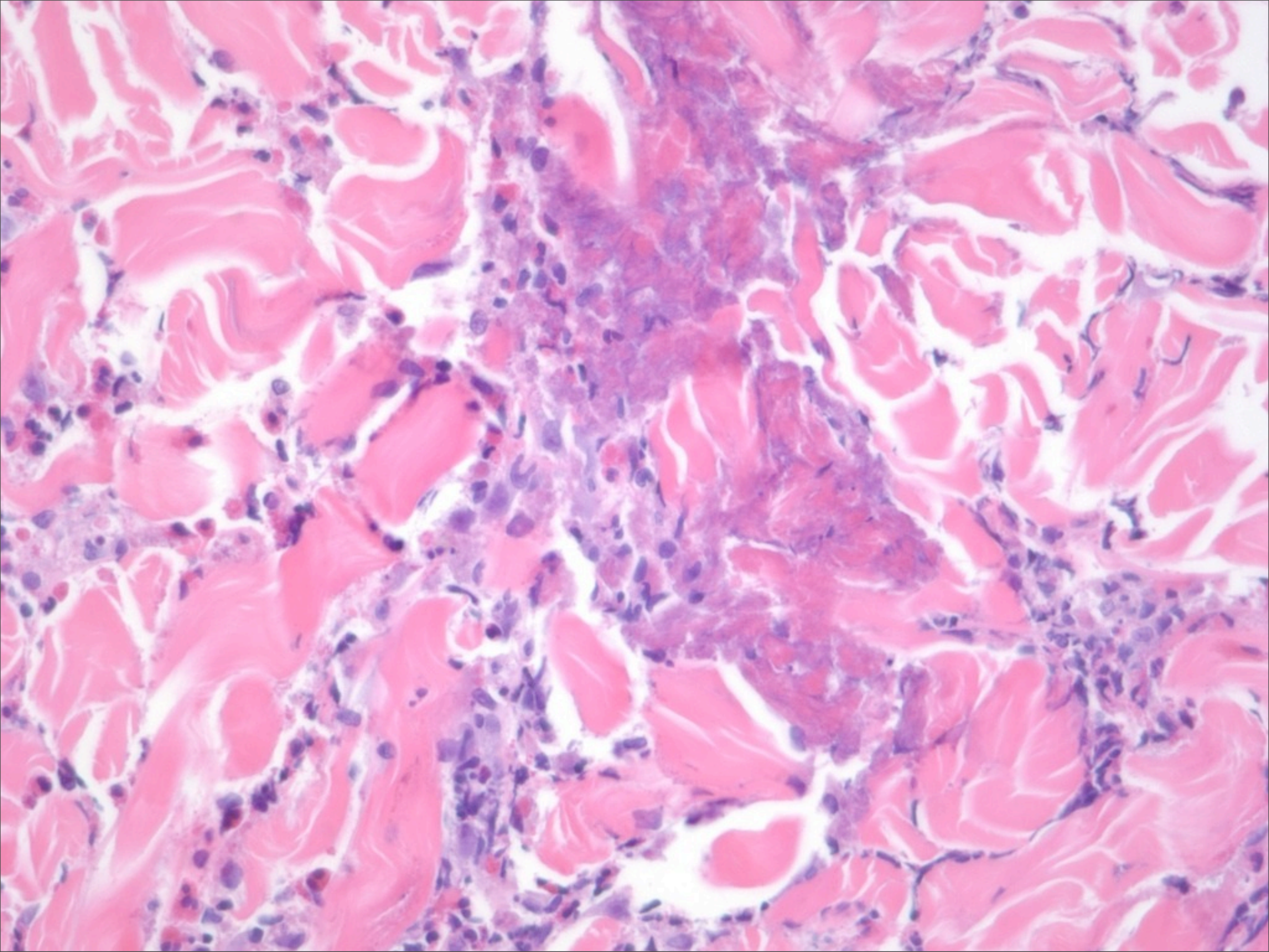
Paul K. Shitabata, M.D.
Dermatopathology Institute
Torrance, CA



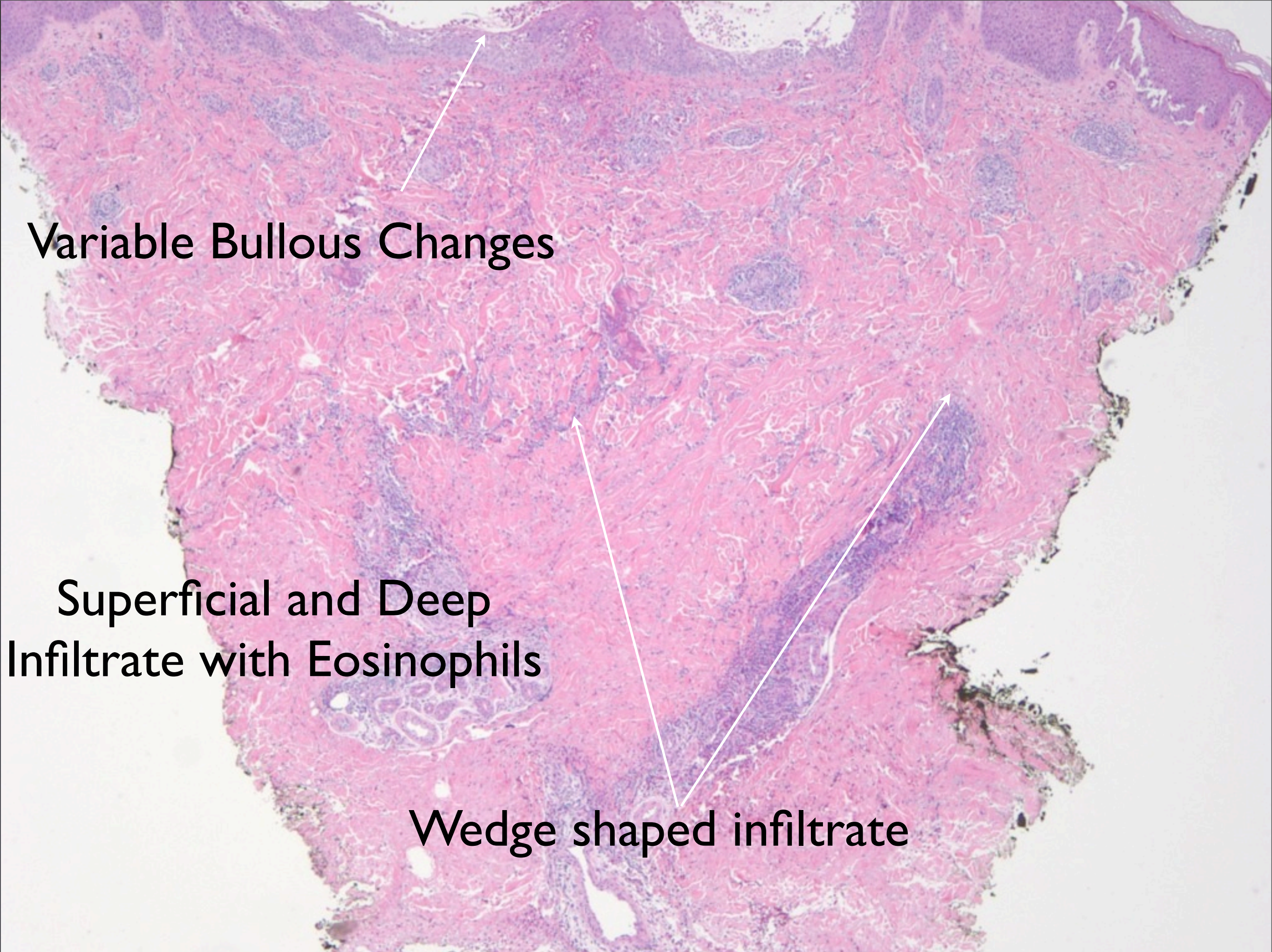








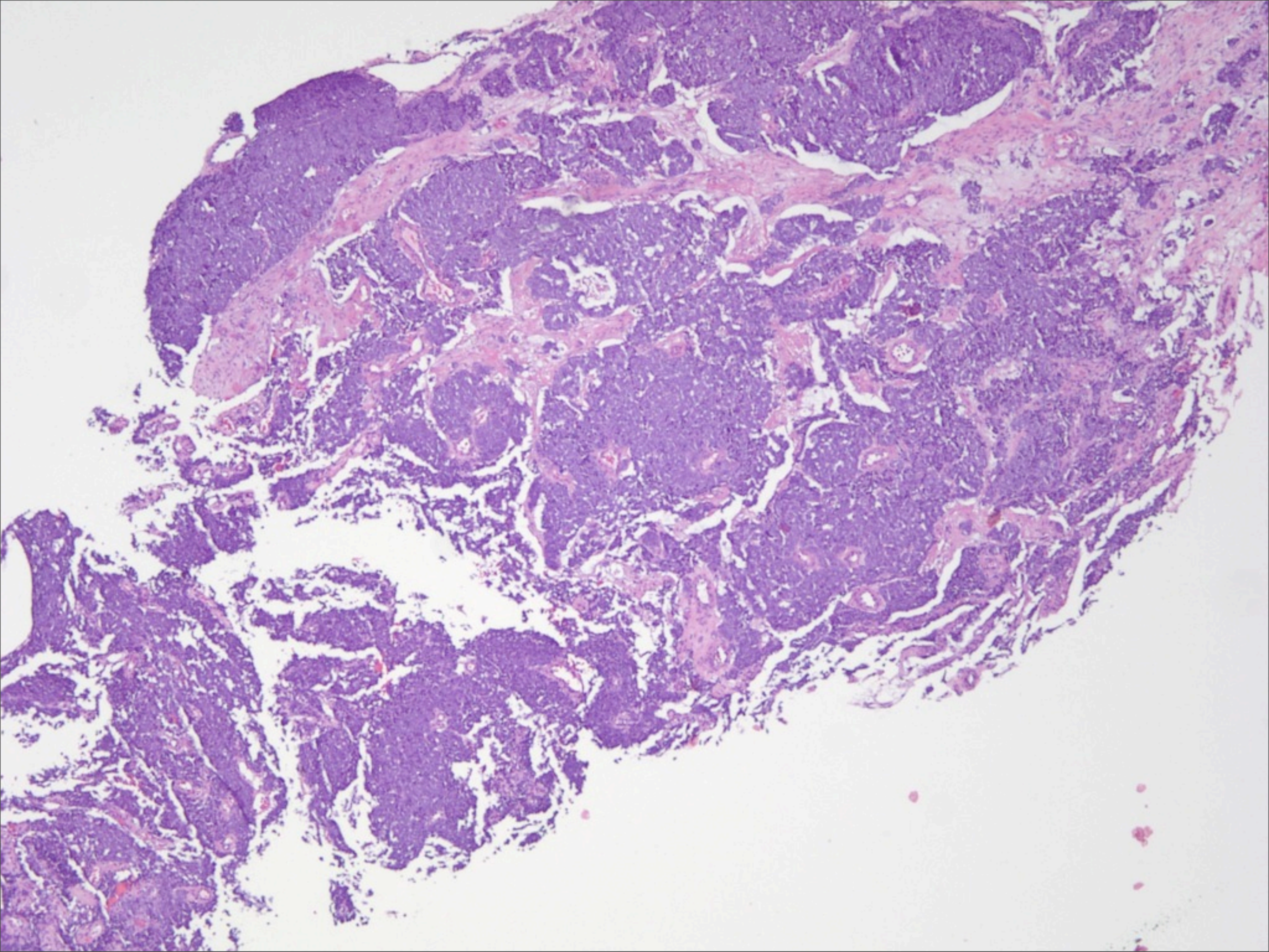
Changes Consistent with Arthropod Bite with Flame Figures

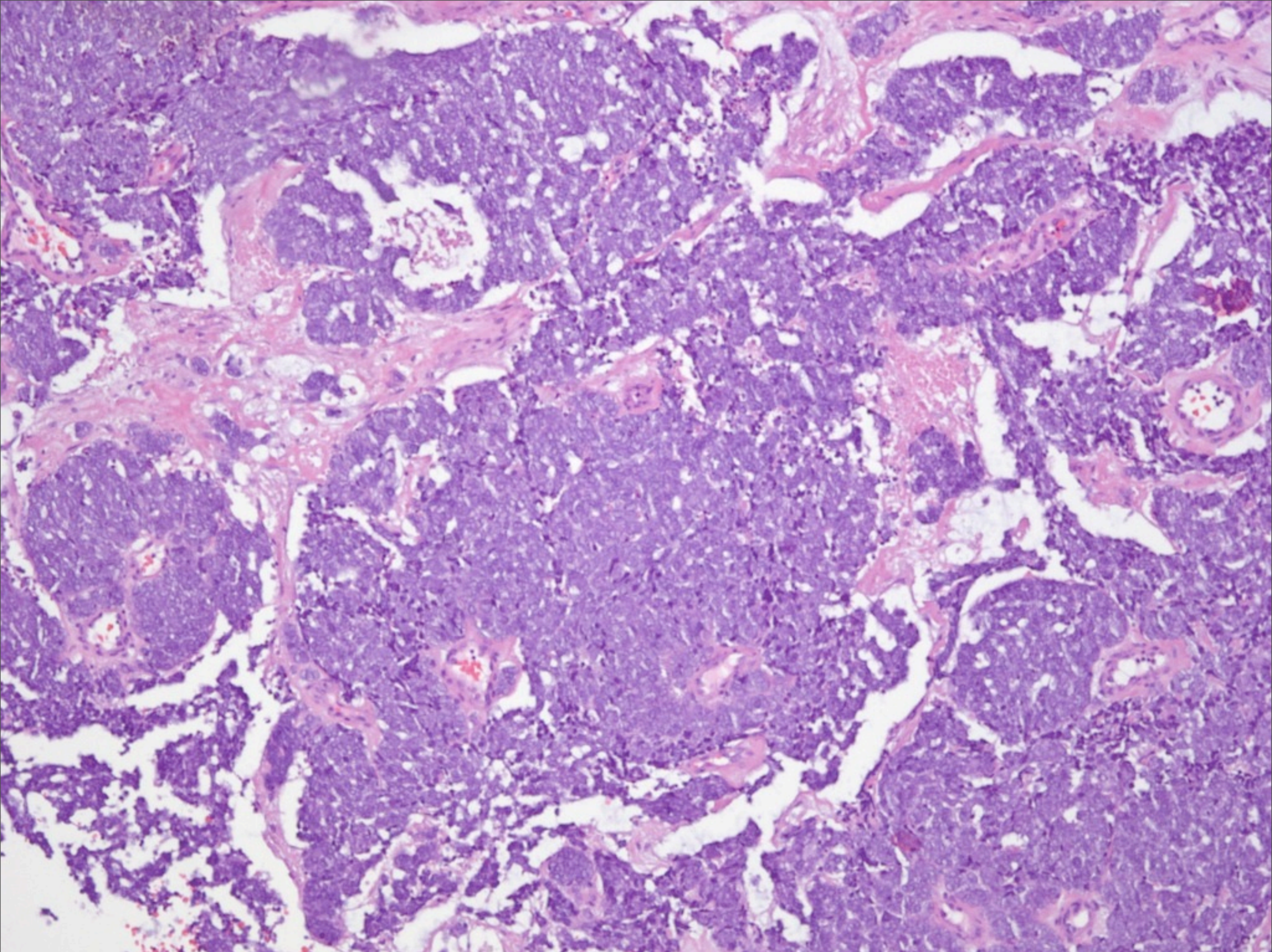


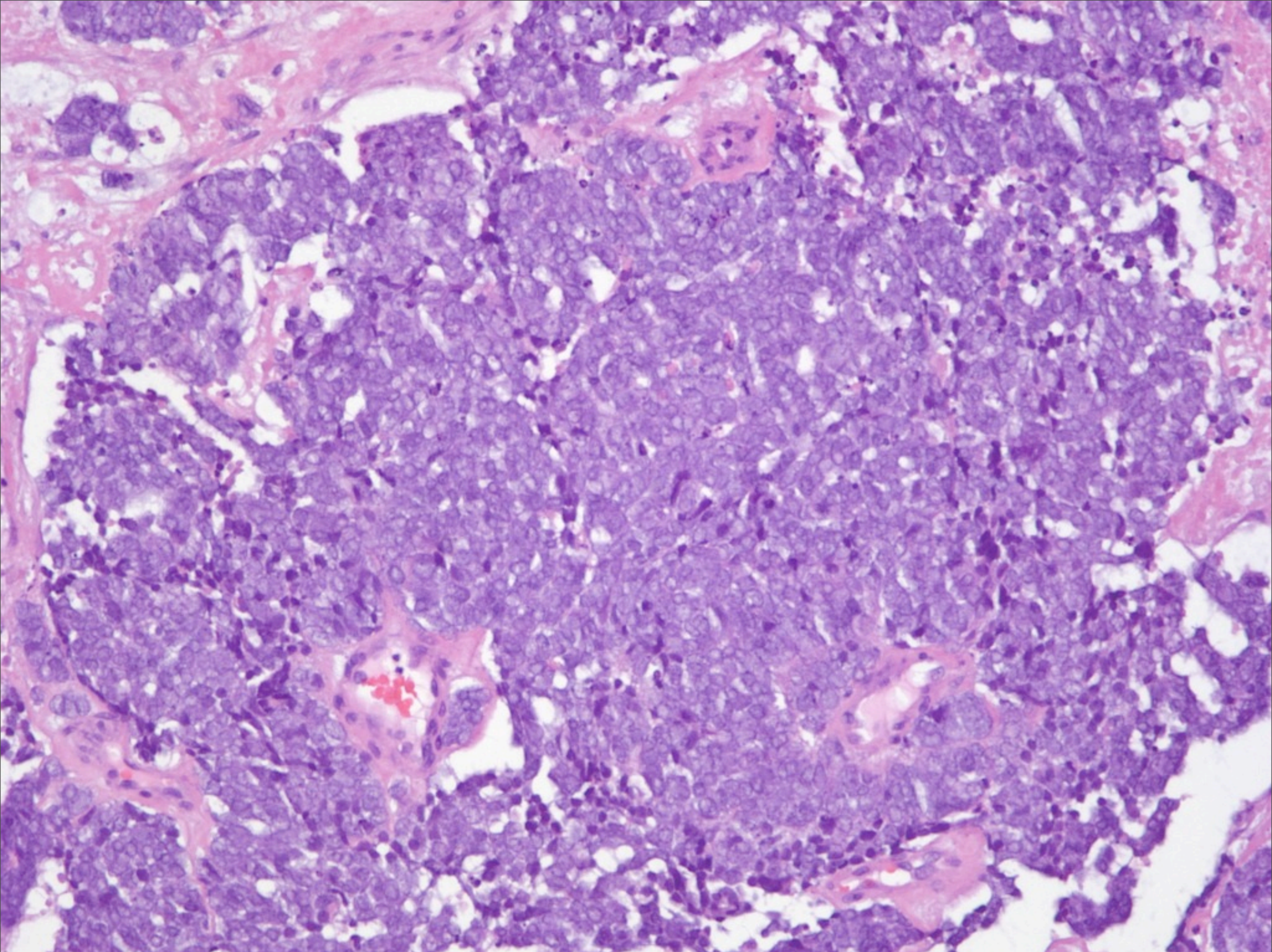
Variable Bullous Changes

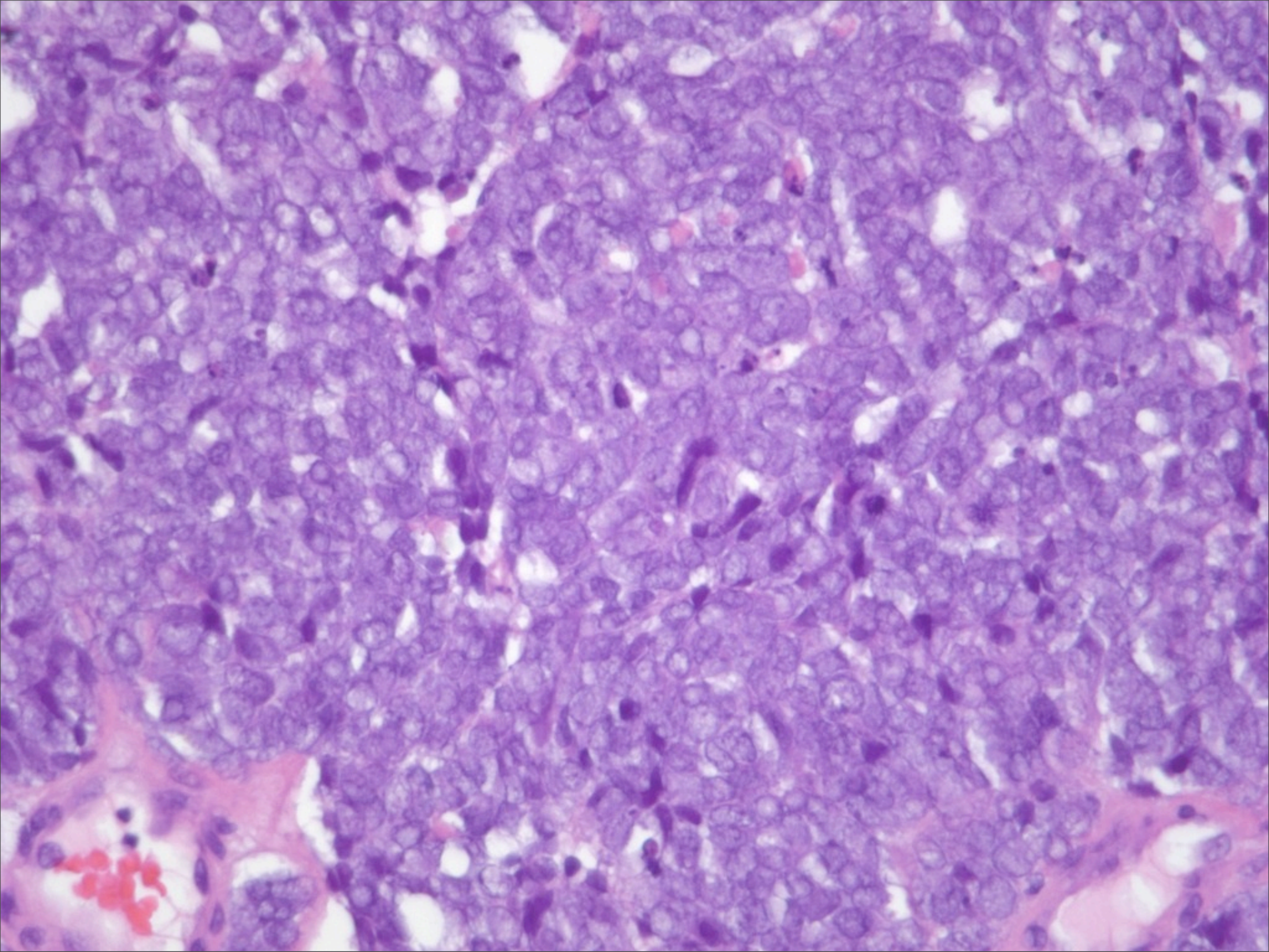
**Superficial and Deep
Infiltrate with Eosinophils**

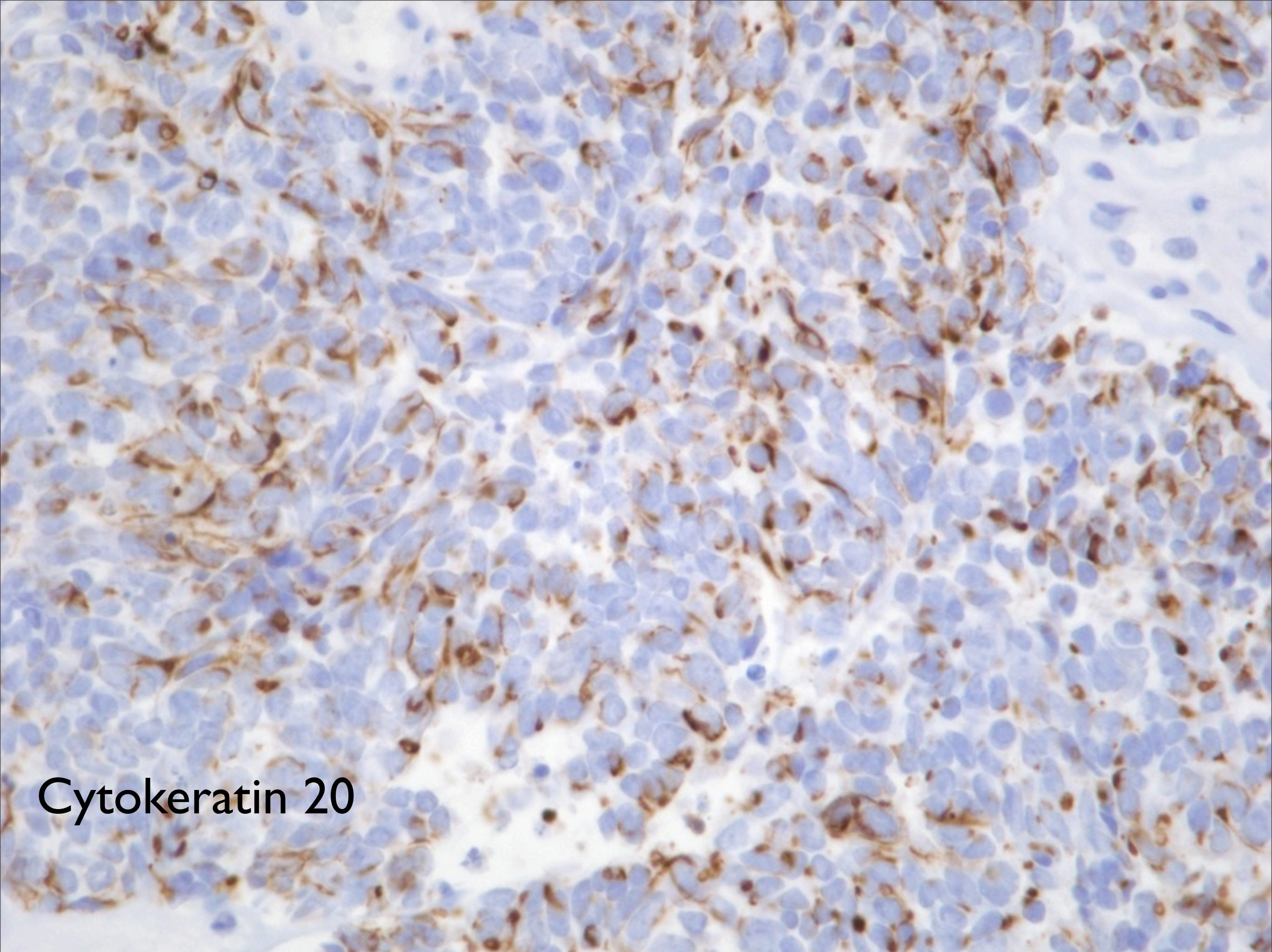
Wedge shaped infiltrate



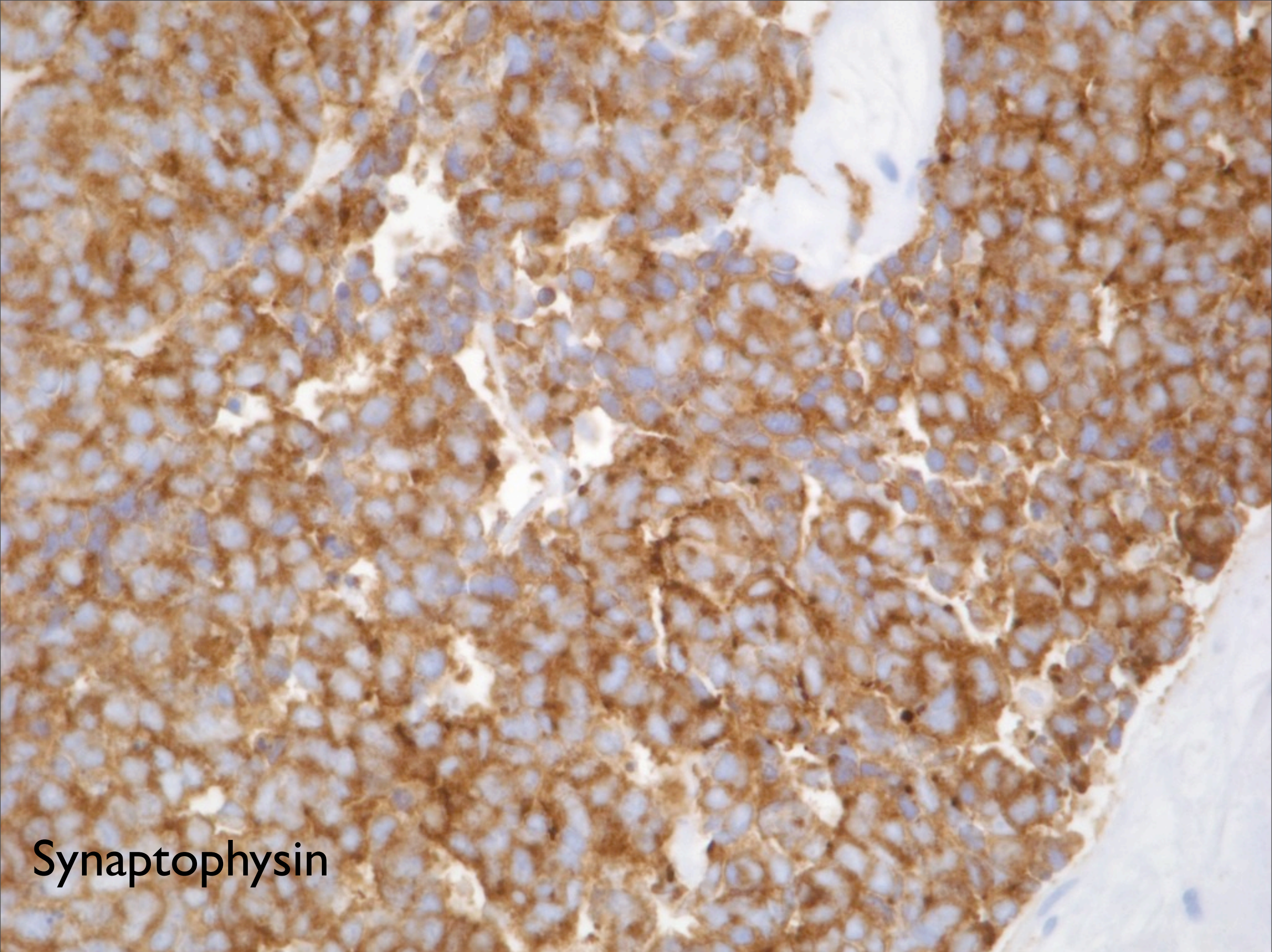








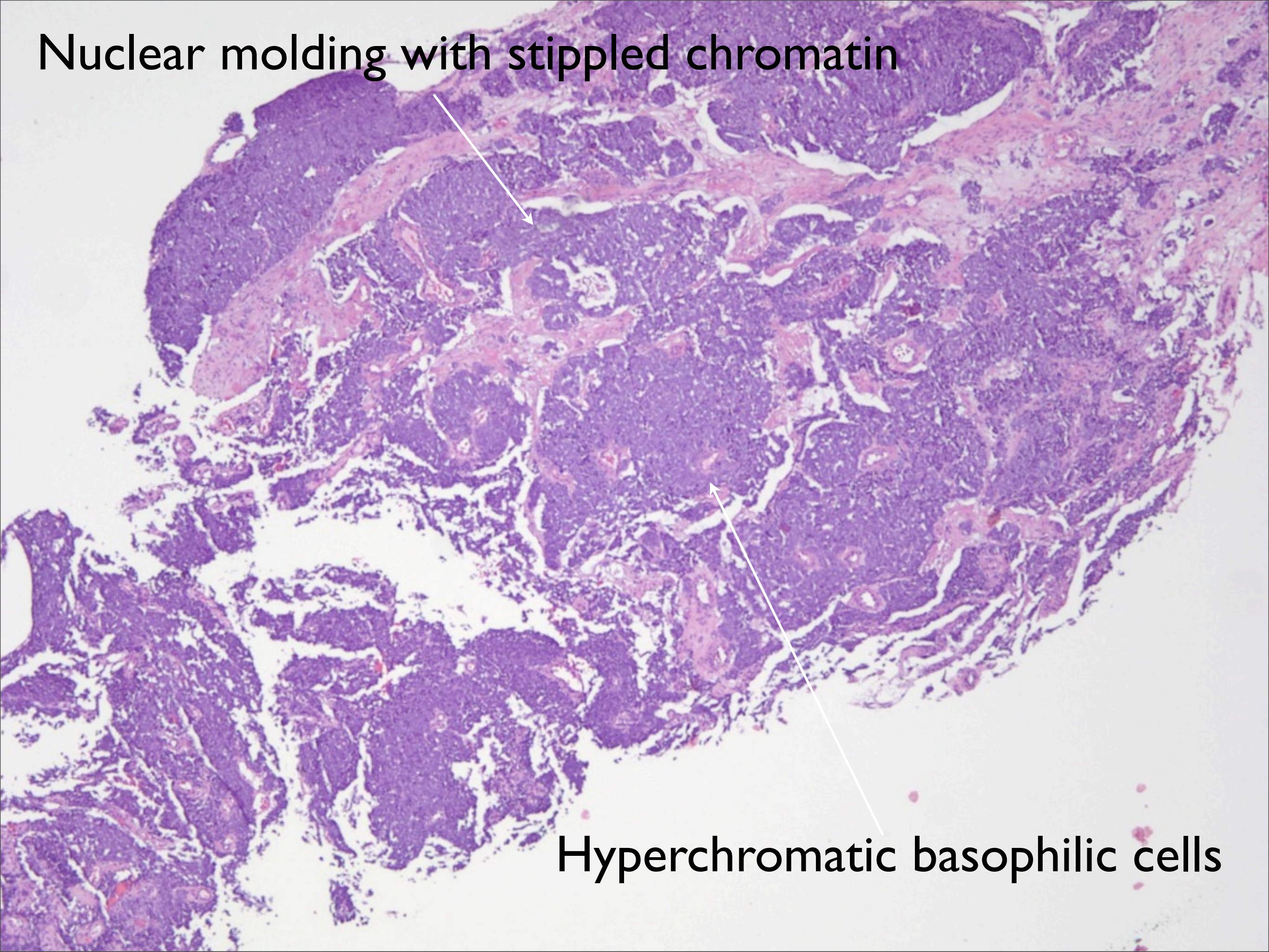
Cytokeratin 20



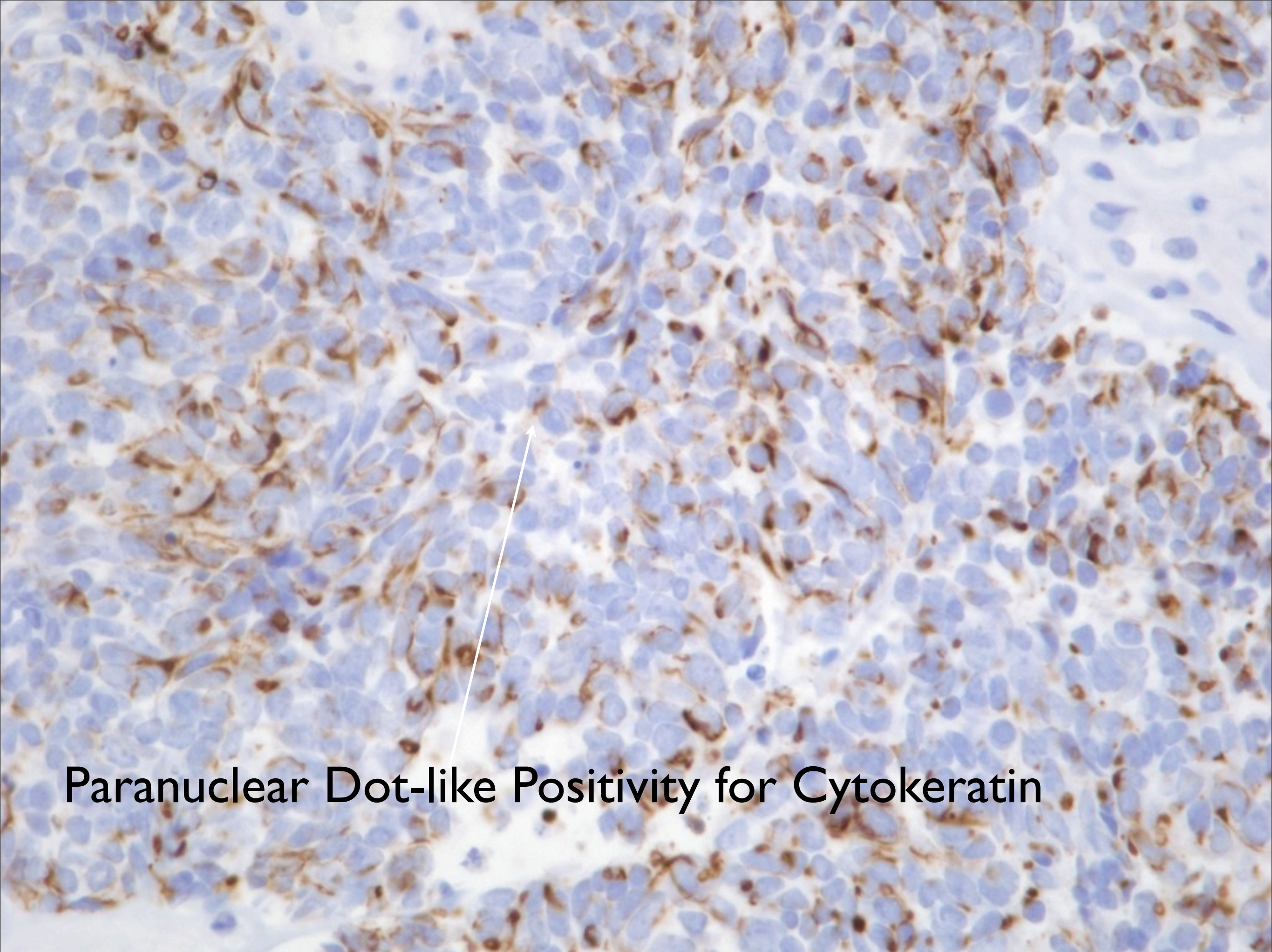
Synaptophysin

Merkel Cell Carcinoma

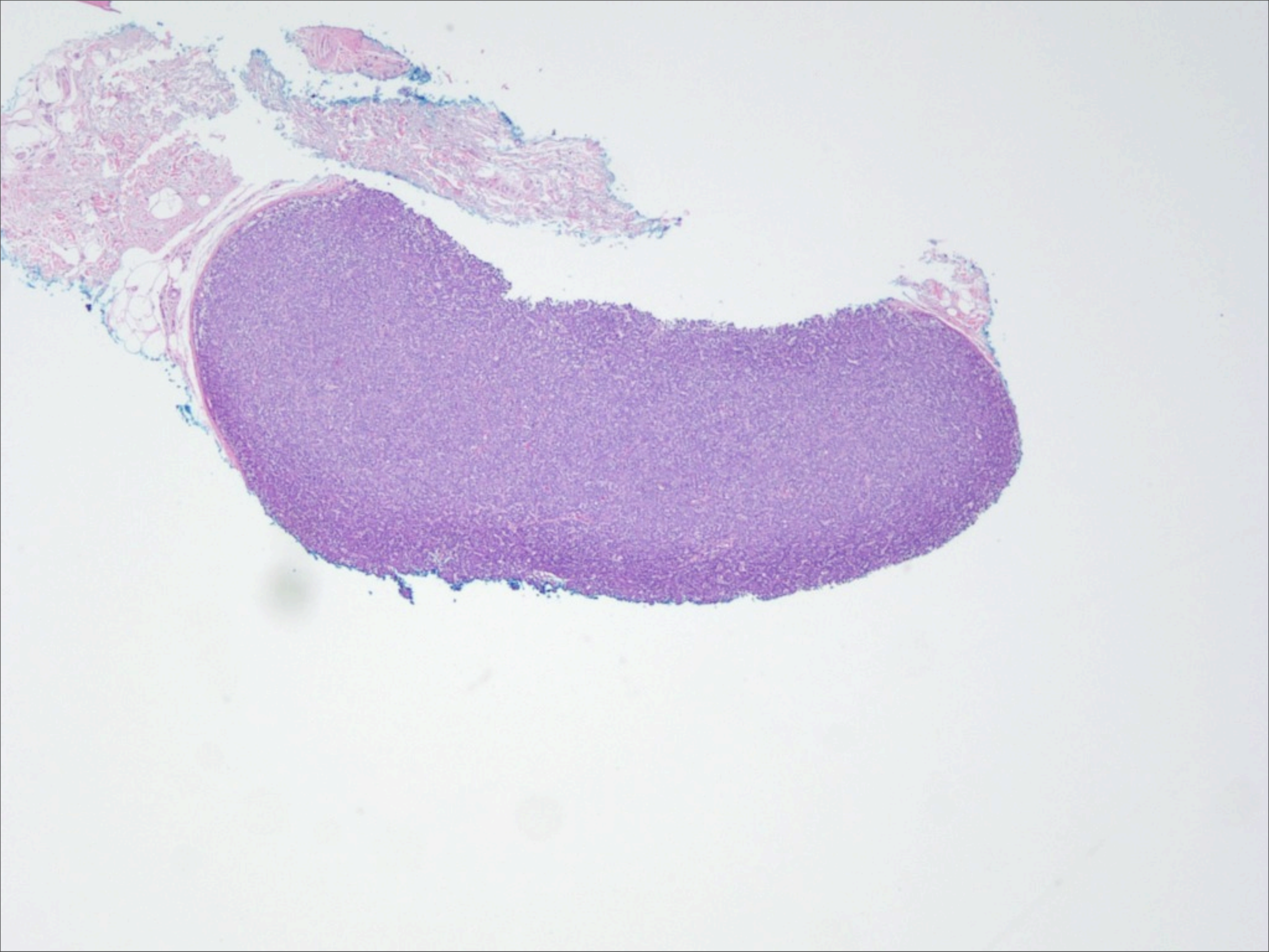
Nuclear molding with stippled chromatin

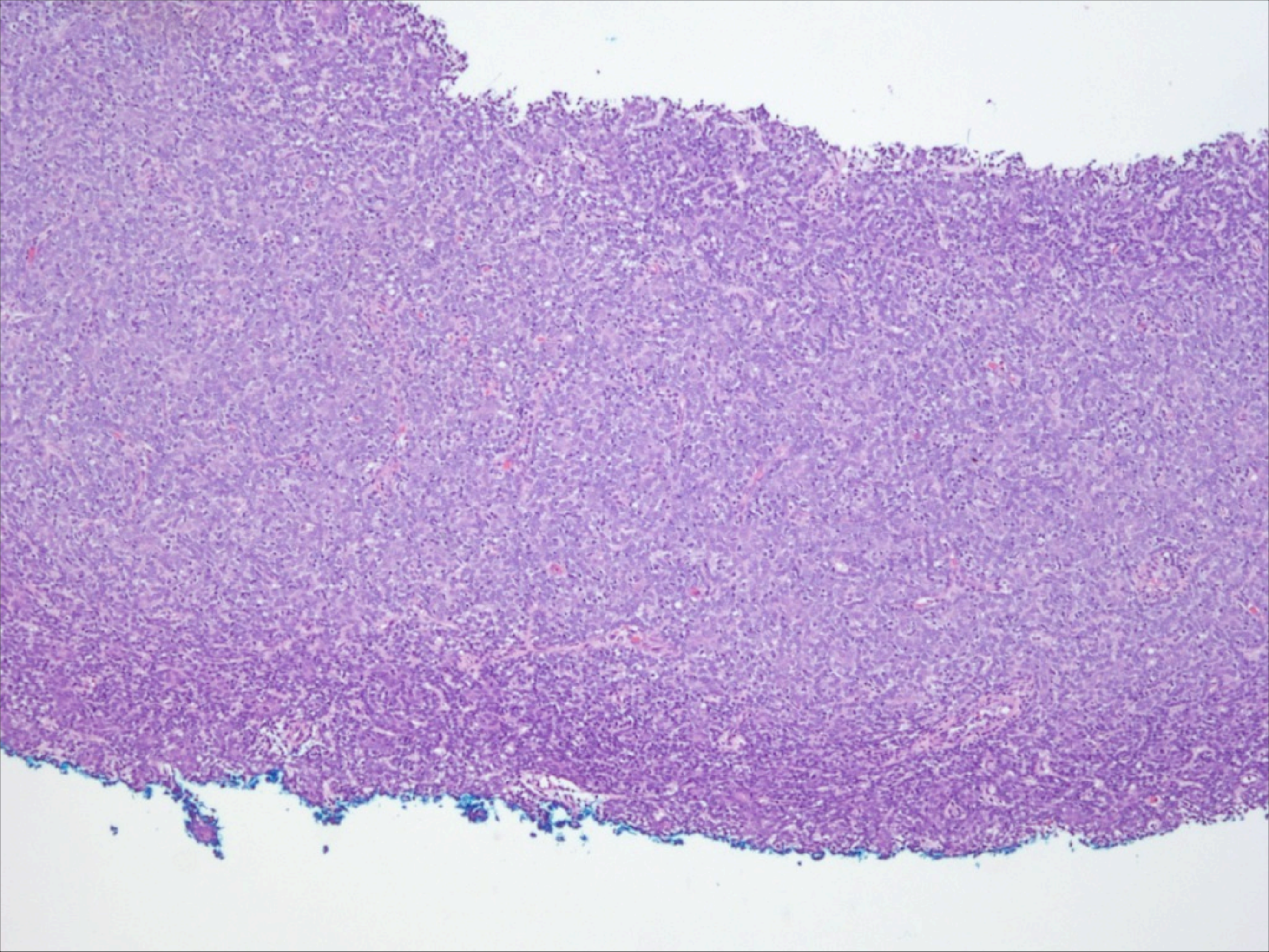


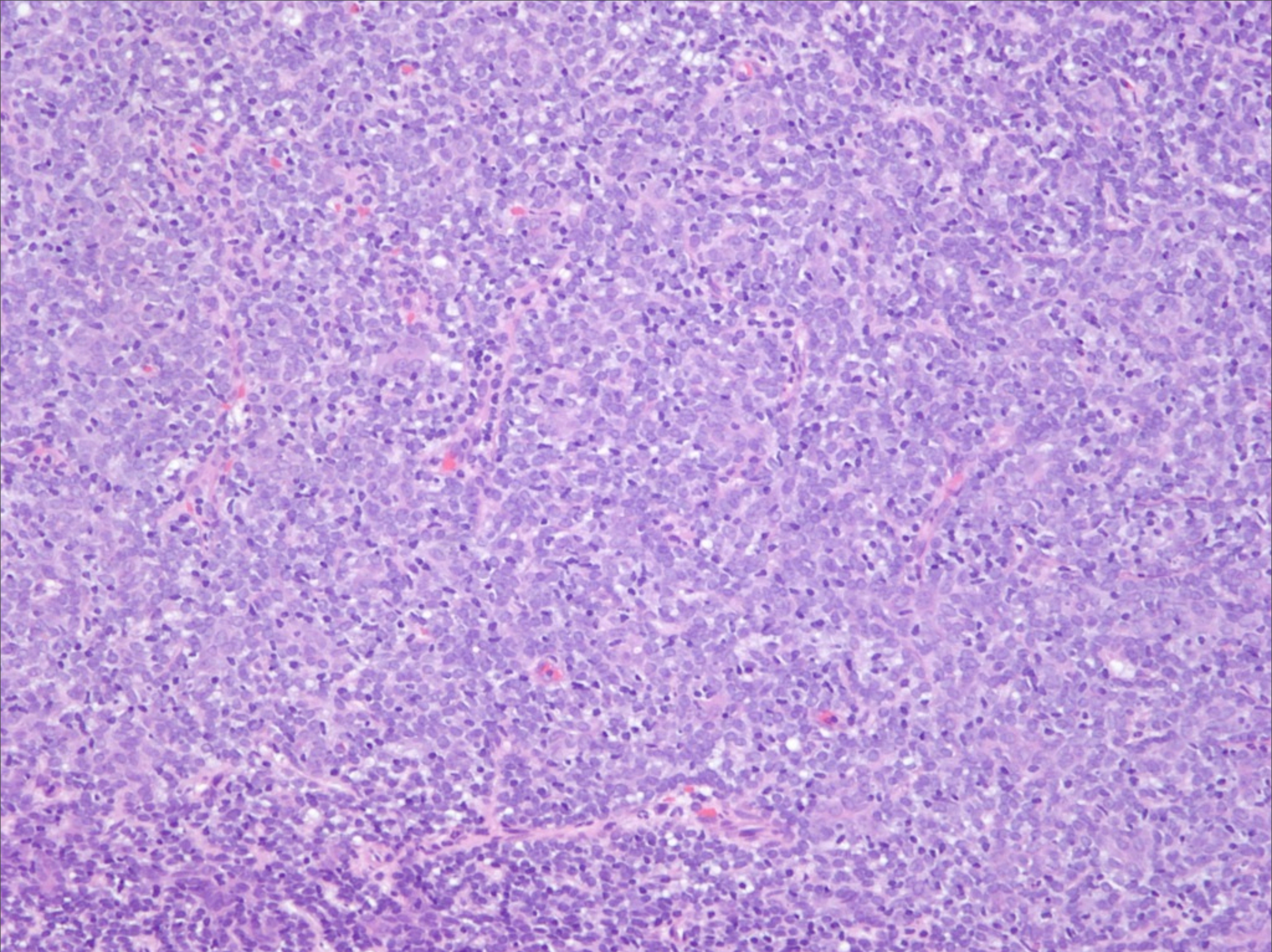
Hyperchromatic basophilic cells

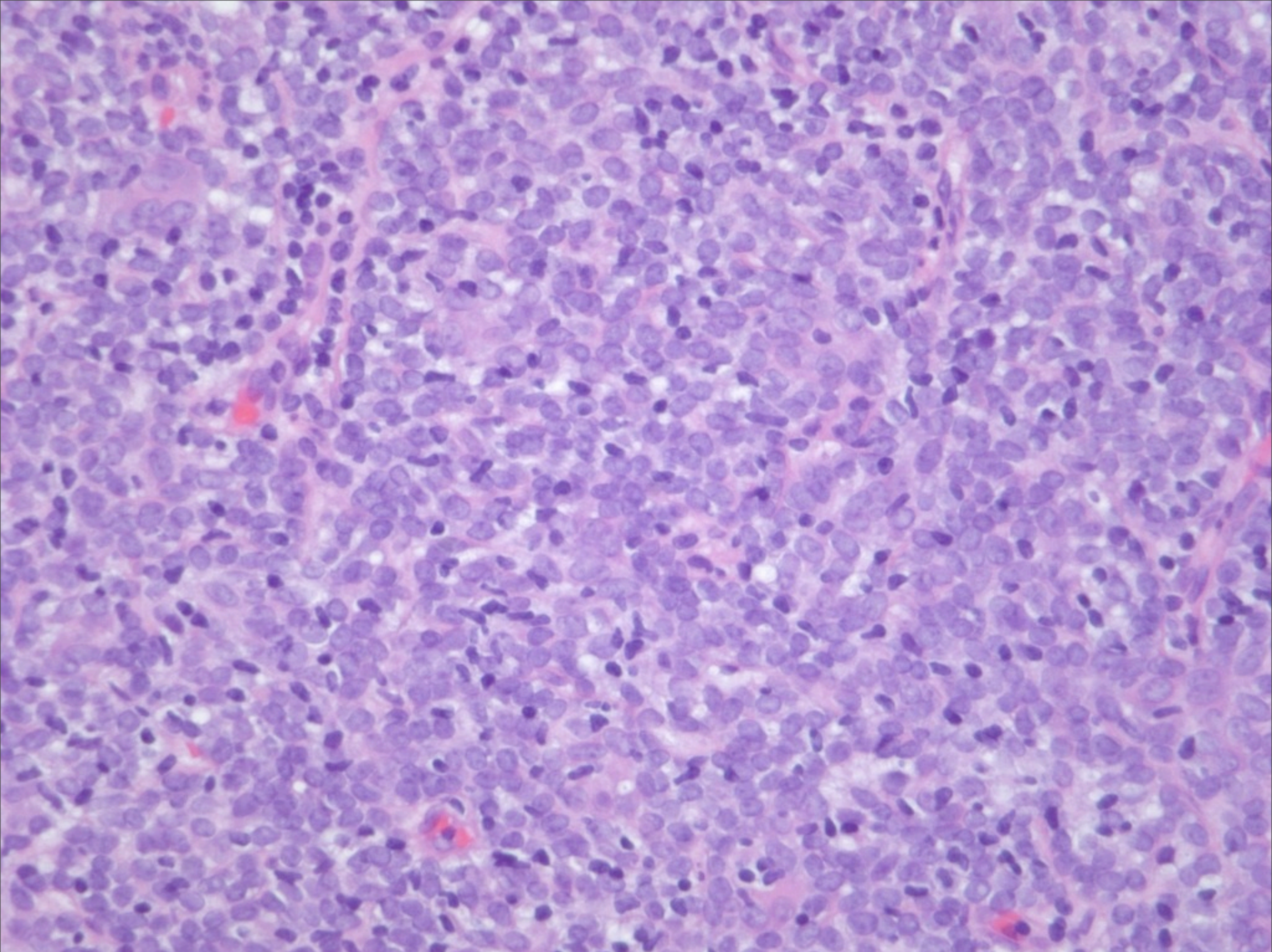


Paraneuclear Dot-like Positivity for Cytokeratin



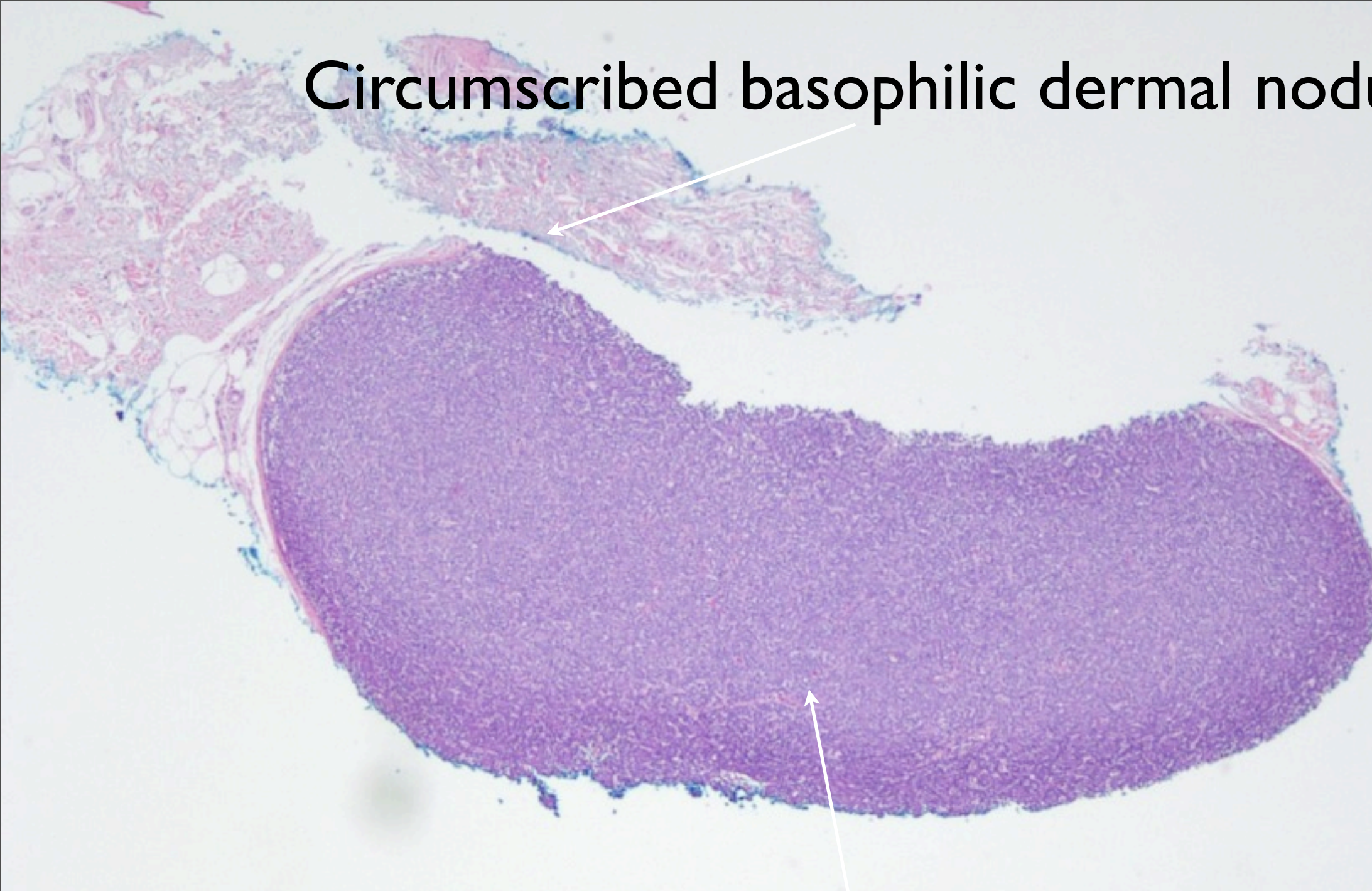



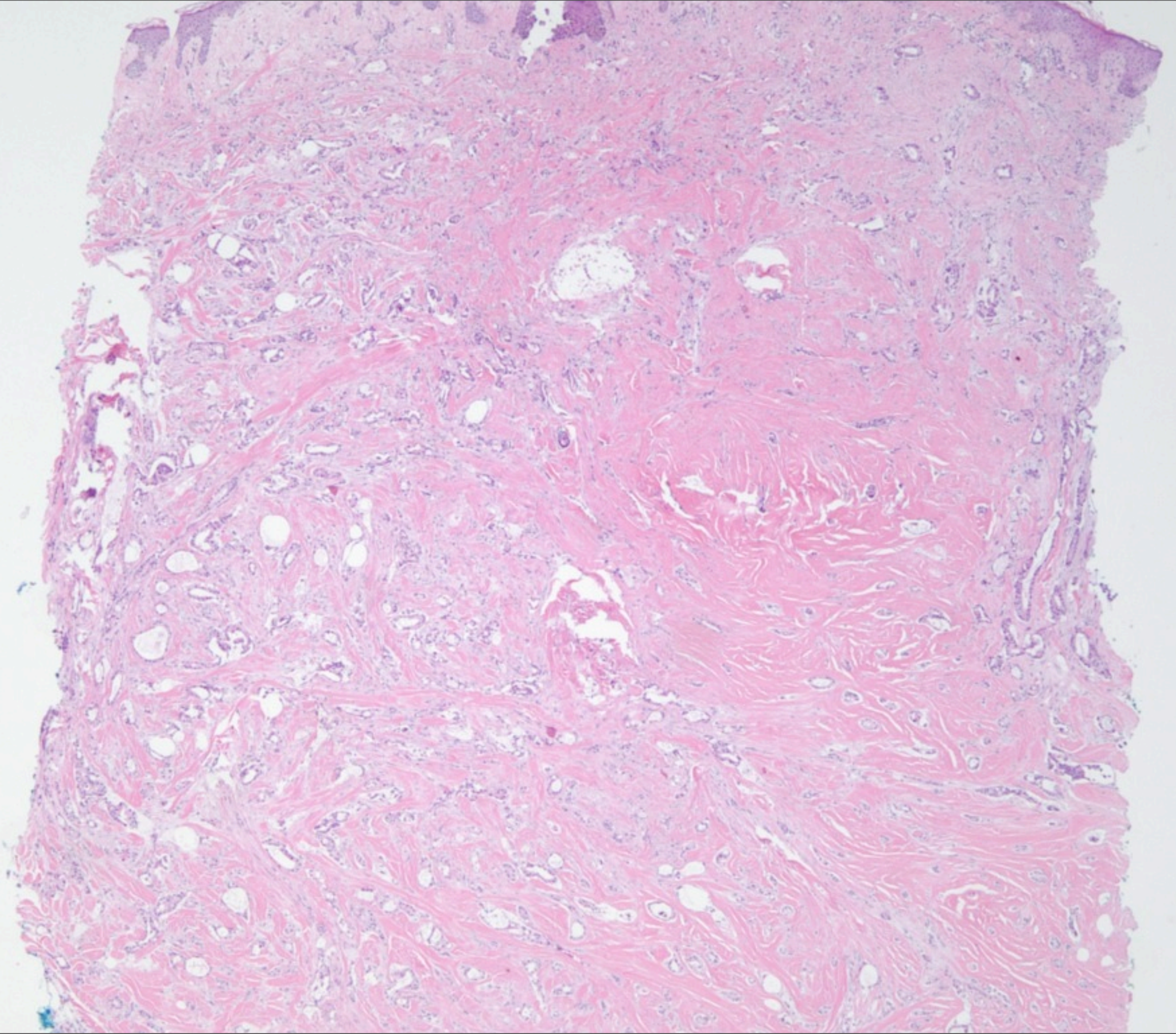


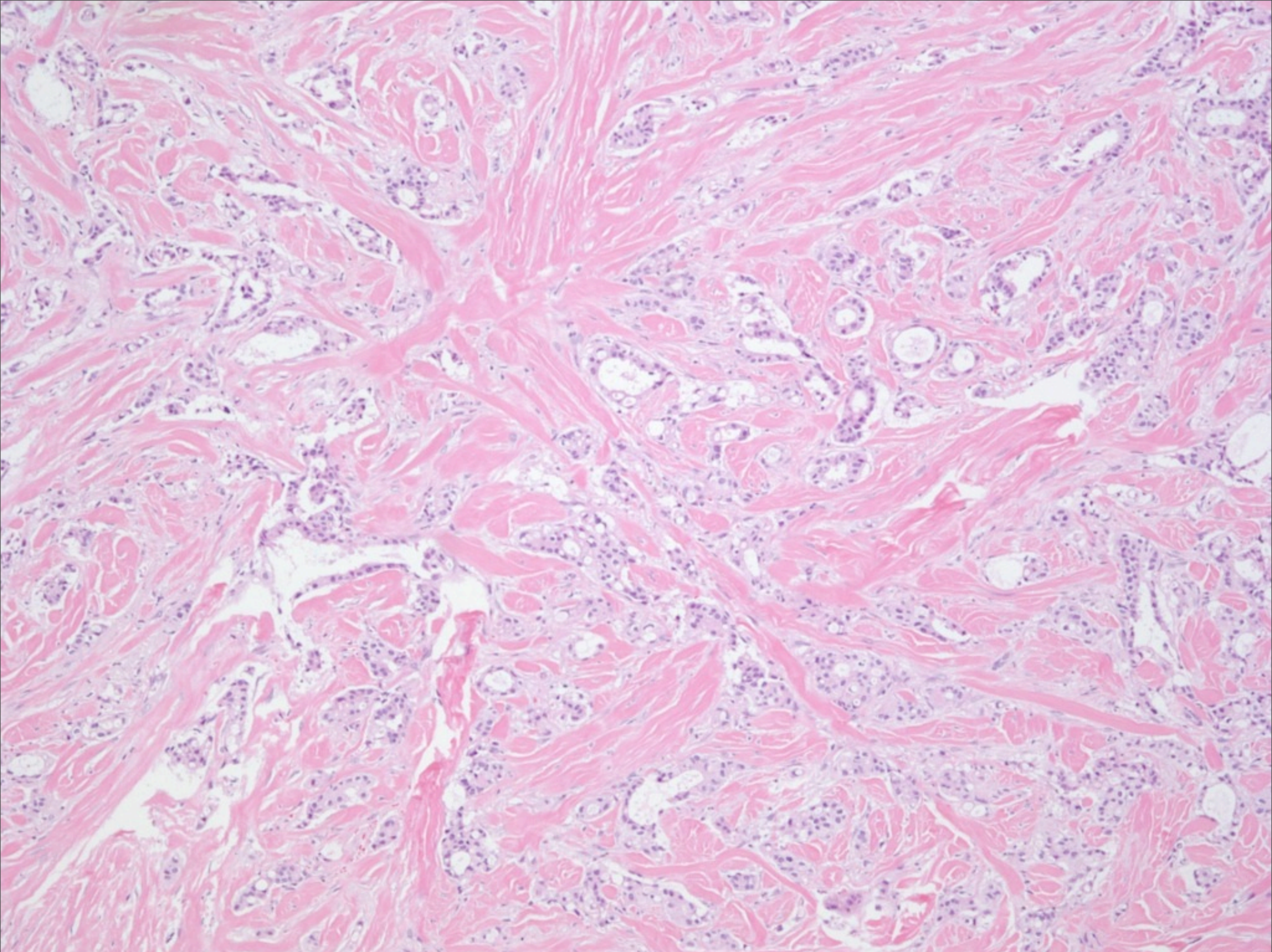
Eccrine Spiradenoma

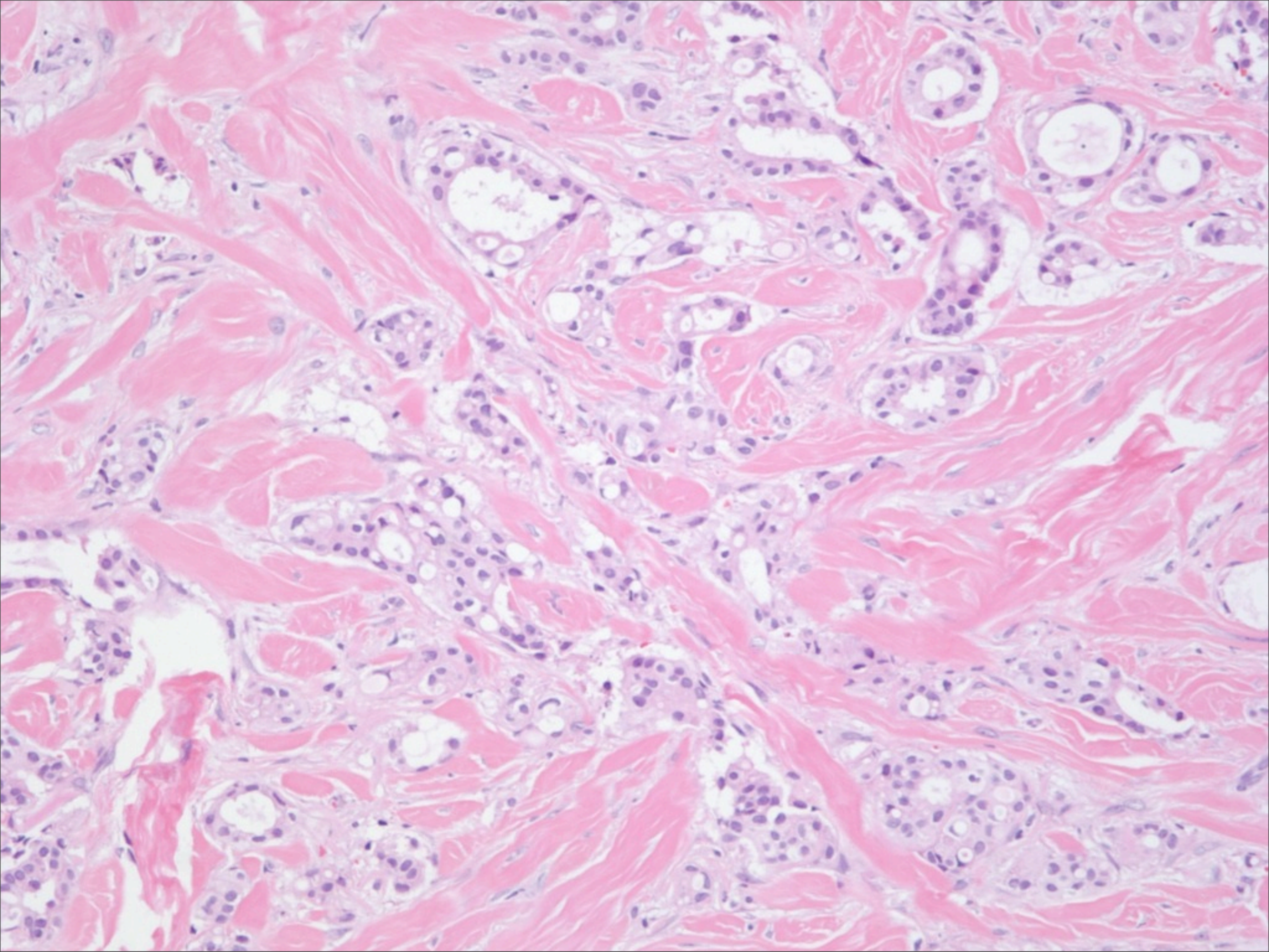
Circumscribed basophilic dermal nodule

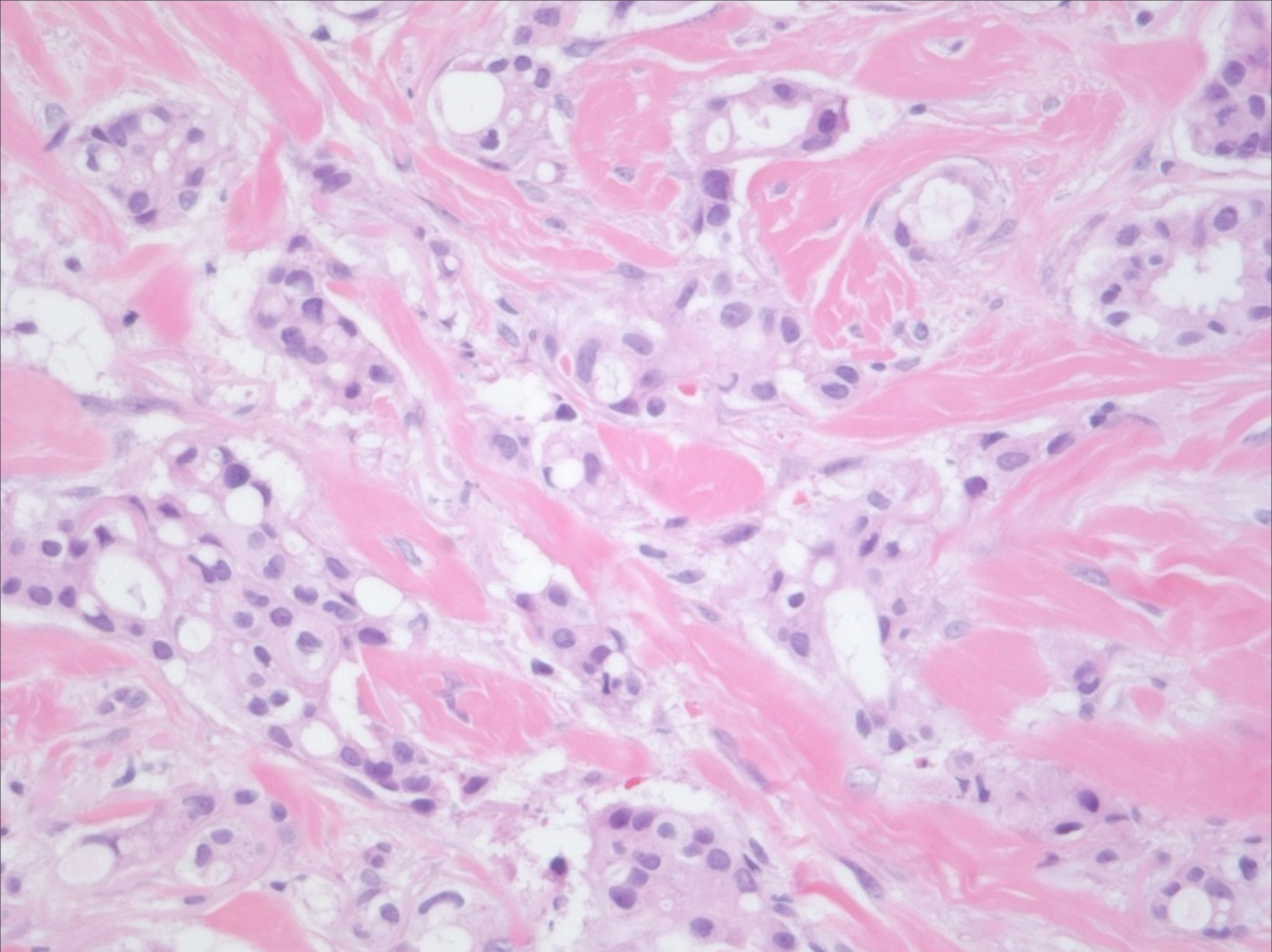


Small basophilic cells with mature lymphocytes



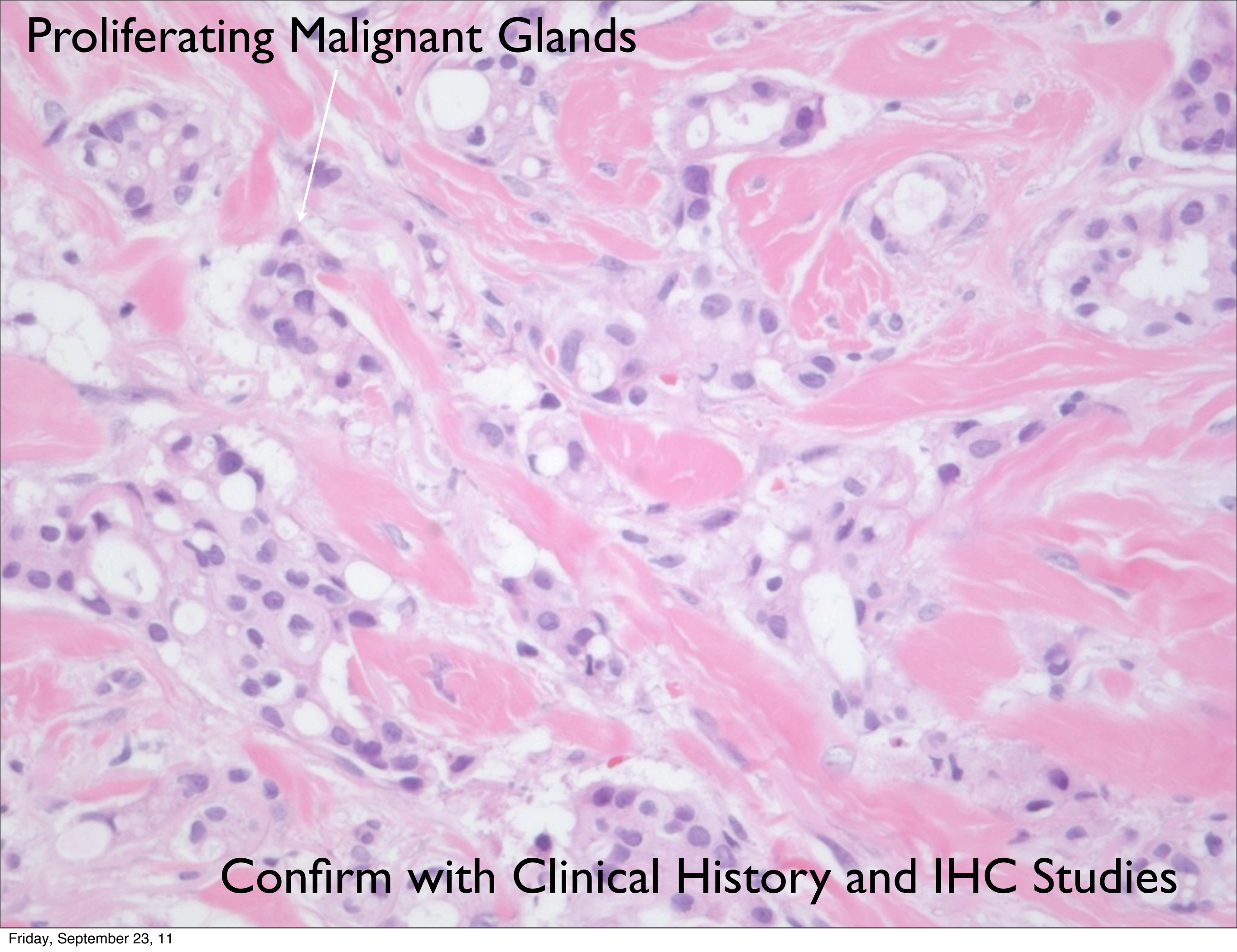




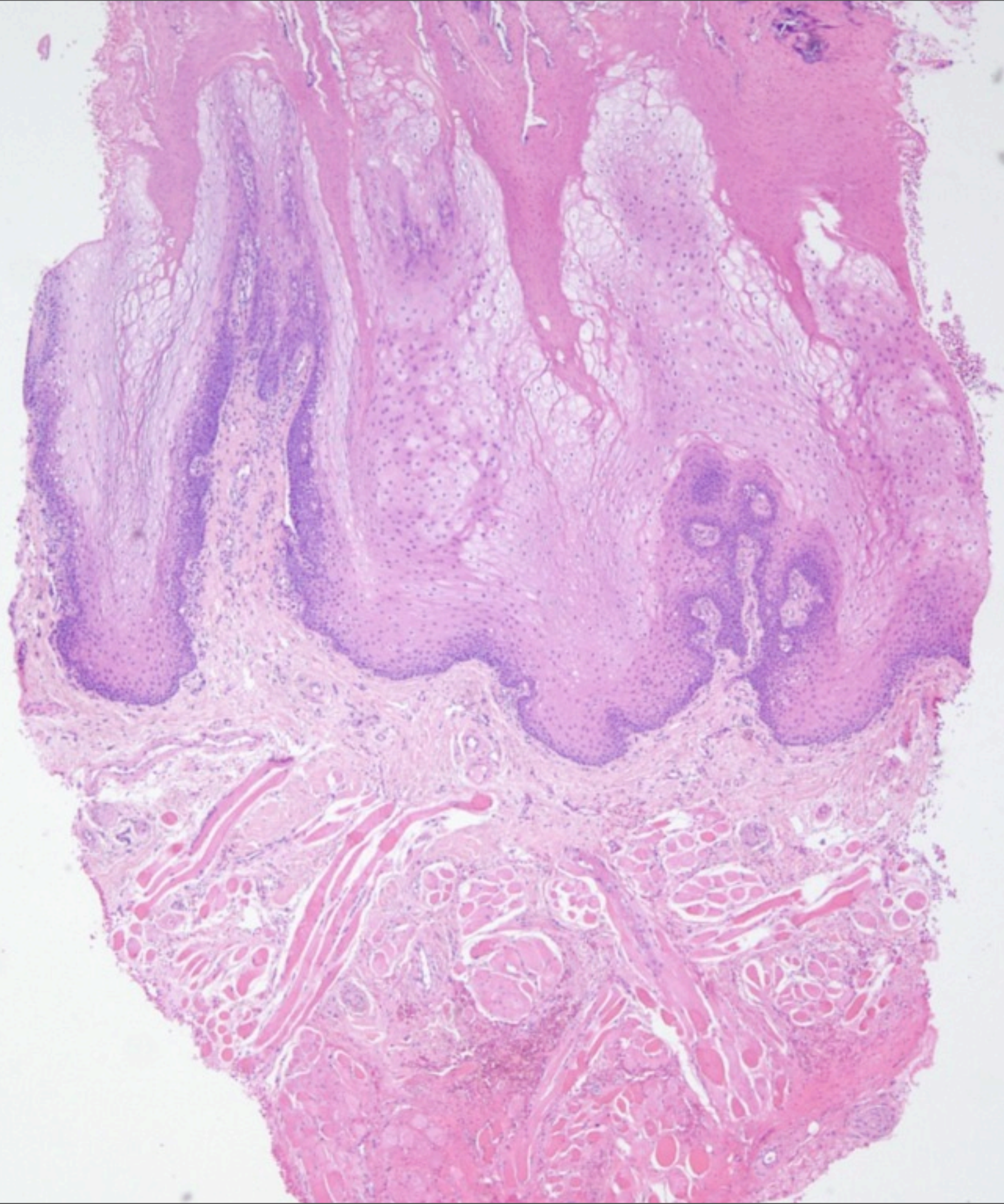


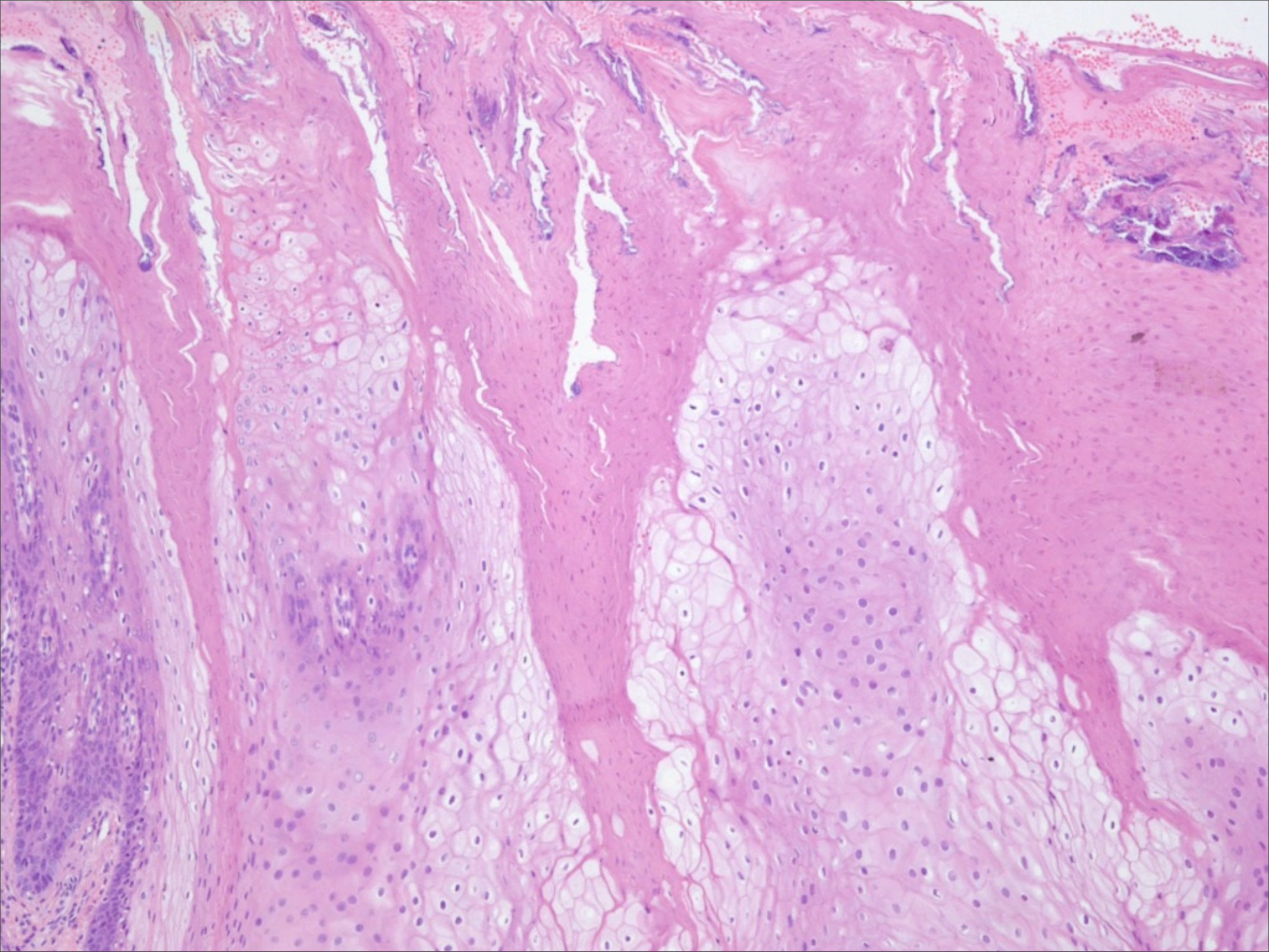
Metastatic Adenocarcinoma, Consistent with Breast Primary

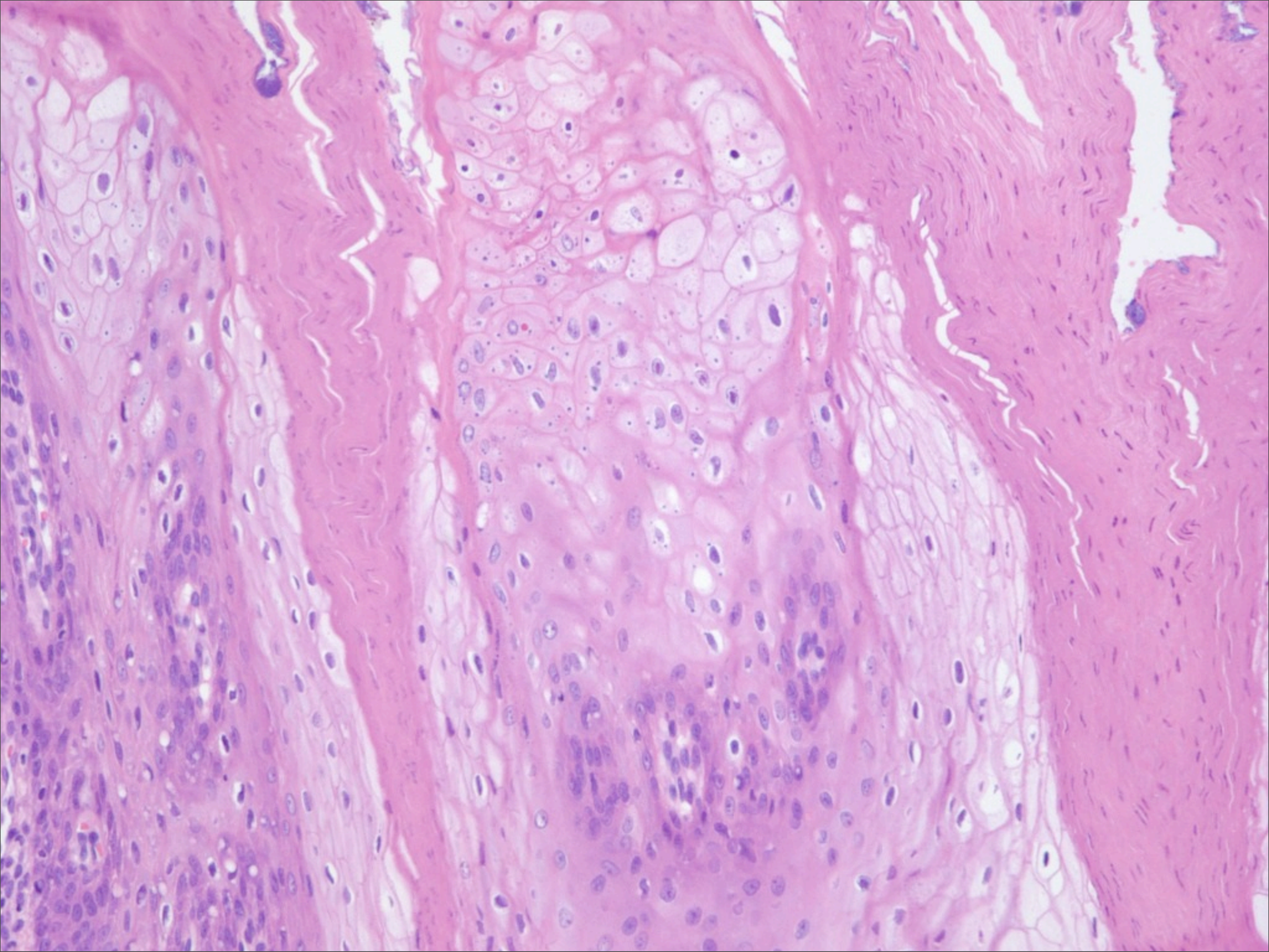
Proliferating Malignant Glands

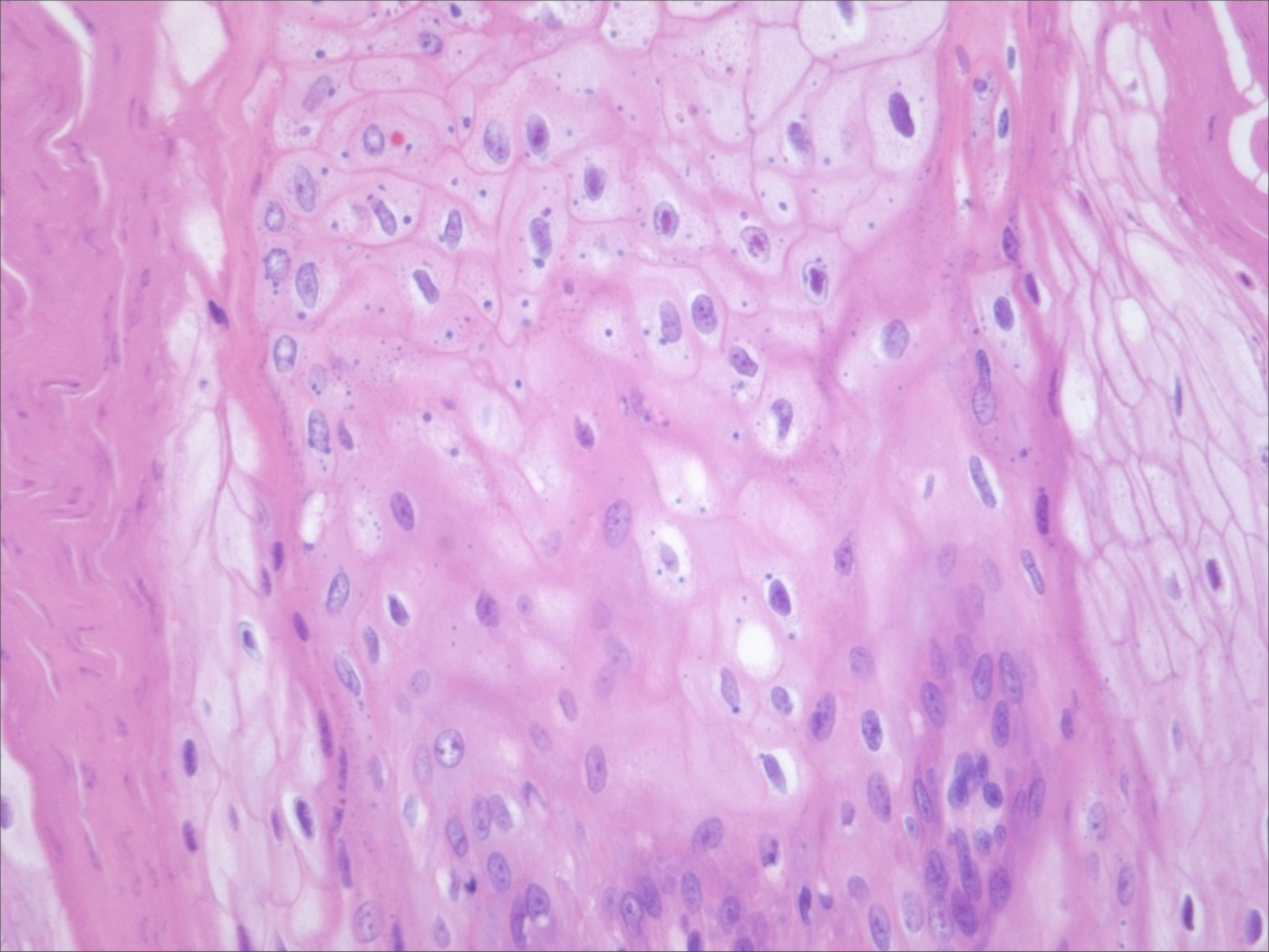


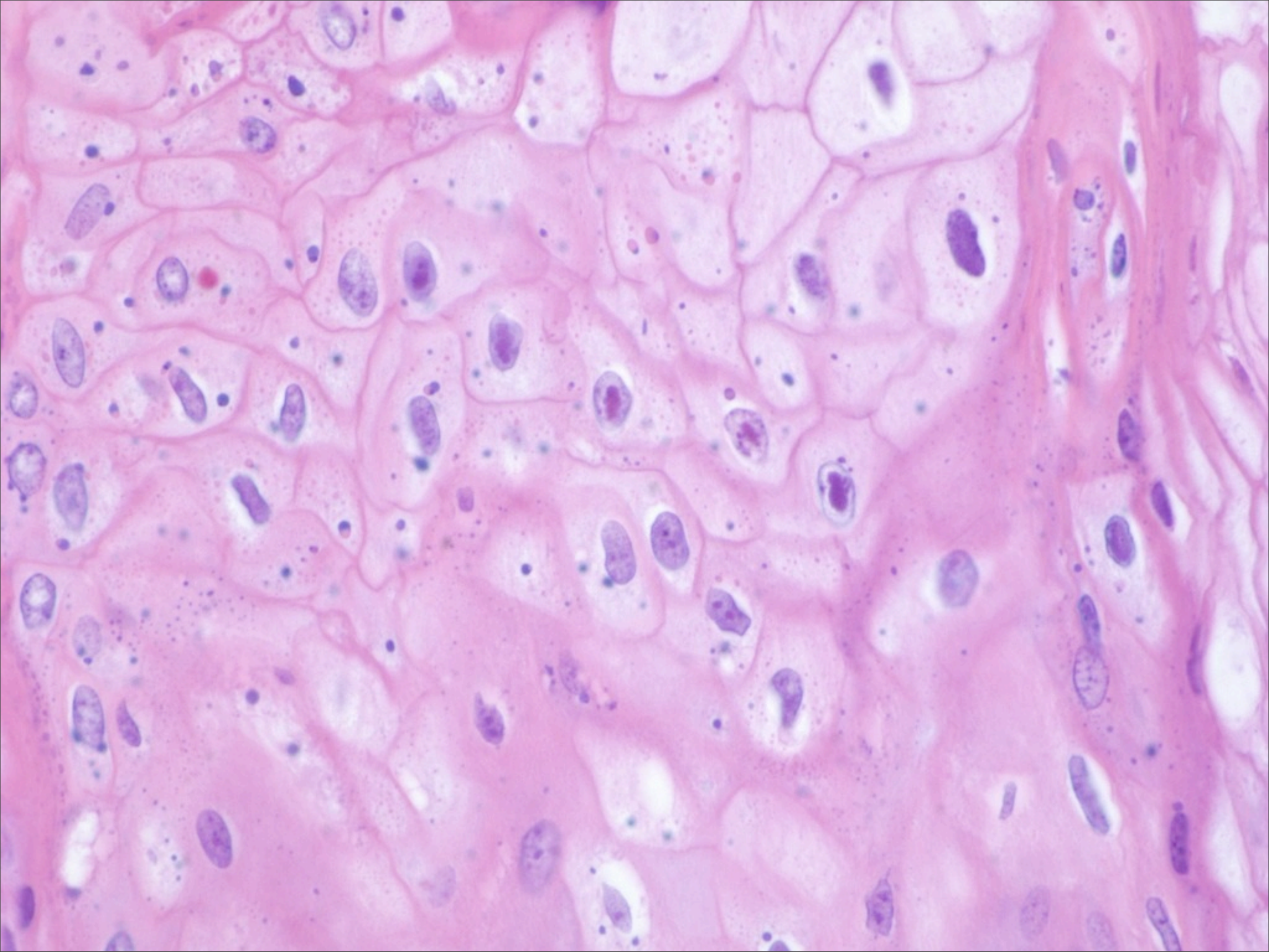
Confirm with Clinical History and IHC Studies

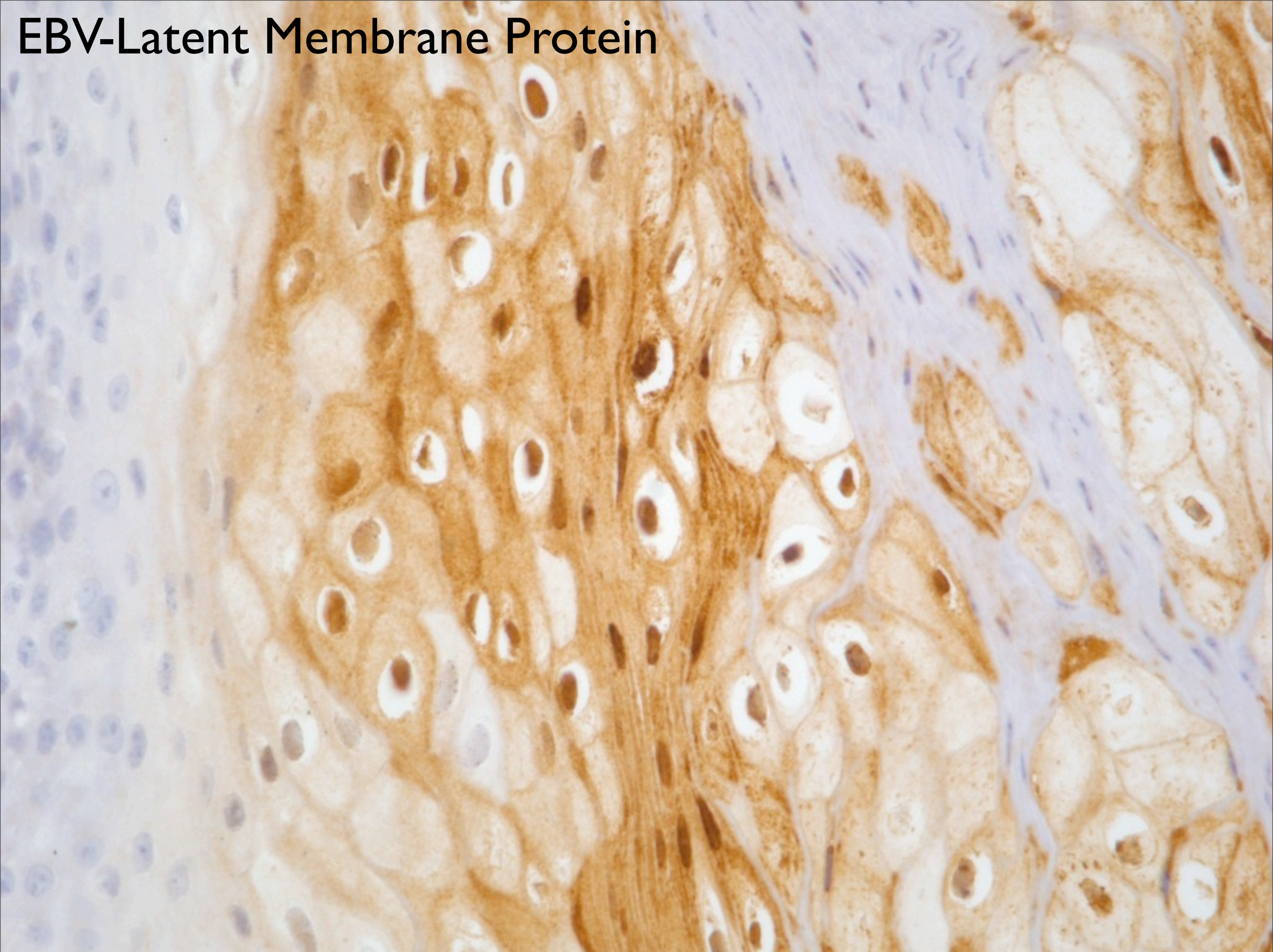




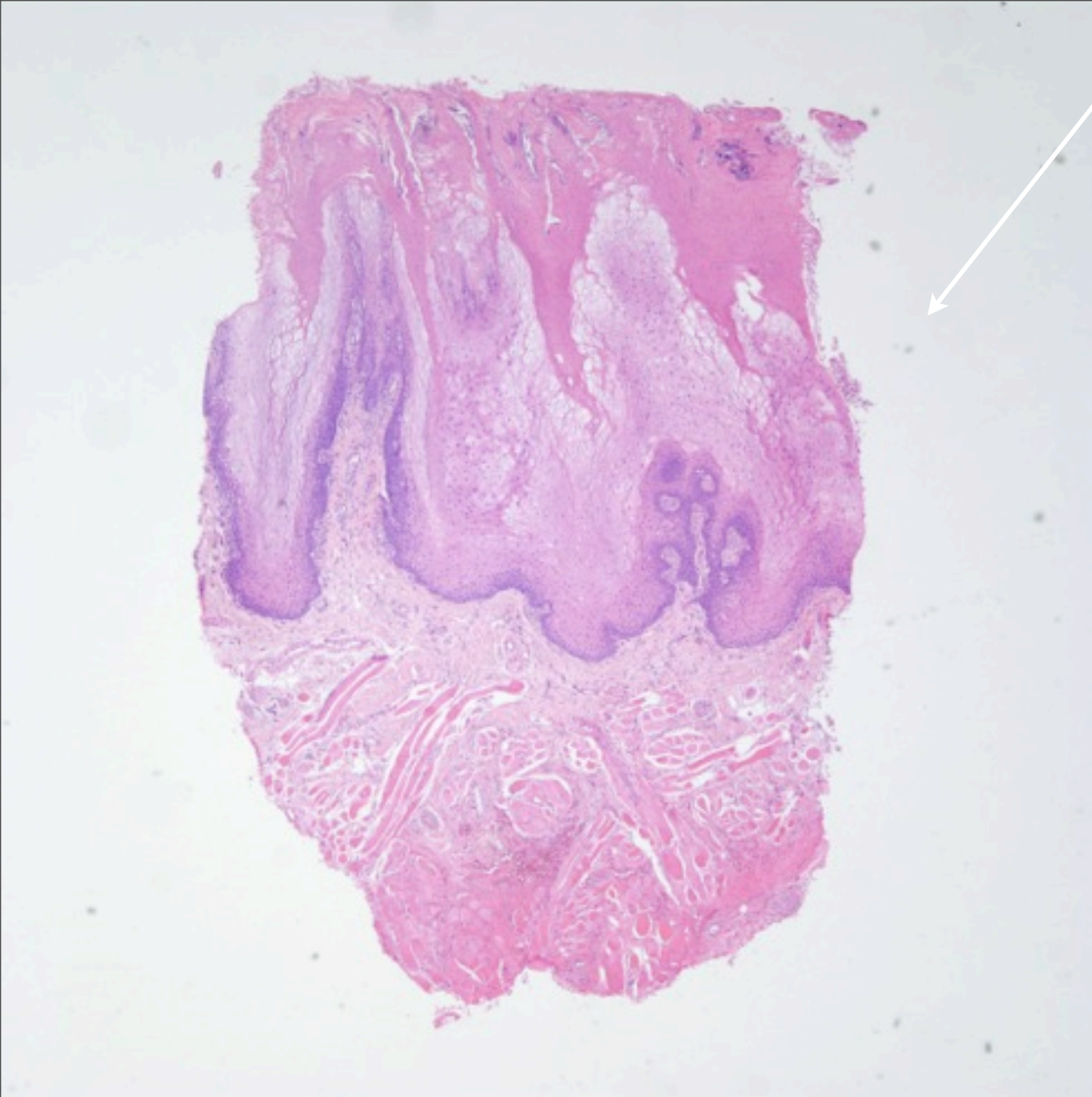








Oral Hairy Leukoplakia



Tongue Mucosa
Acanthosis with
Papillomatosis

Viral Intranuclear Inclusions

